



OPEN ACCESS

Percutaneous auricular nerve stimulation (neuromodulation) for the treatment of pain following outpatient surgery: a proof-of-concept case series

Brian M Ilfeld ¹, John J Finneran IV ¹, David Dalstrom,² Anne M Wallace,³ Baharin Abdullah ¹, Engy T Said ¹

¹Department of Anesthesiology, University of California San Diego, La Jolla, California, USA

²Department of Orthopedic Surgery, University of California San Diego, La Jolla, California, USA

³Department of Surgery, University of California San Diego, La Jolla, California, USA

Correspondence to

Dr Brian M Ilfeld, Anesthesiology, University of California, San Diego, La Jolla, California, USA; bilfeld@health.ucsd.edu

Received 5 May 2022
Accepted 10 June 2022

ABSTRACT

Background Following outpatient surgery, it is often difficult to provide adequate analgesia while concurrently minimizing opioid requirements. Ultrasound-guided percutaneous peripheral nerve stimulation has been proposed as an analgesic, but requires physician-level skills, advanced equipment, up to an hour to administer, and is frequently cost prohibitive. In contrast, percutaneous auricular neuromodulation may be placed by nursing staff in a few minutes without additional equipment, theoretically provides analgesia for nearly any anatomic location, lacks systemic side effects, and has no significant risks. We now present a case report to demonstrate proof of concept for the off-label use of an auricular neuromodulation device—originally developed to treat symptoms associated with opioid withdrawal—to instead provide analgesia following outpatient surgery.

Case presentation Following moderately painful ambulatory orthopedic and breast surgery, seven patients had an auricular neuromodulation device (NSS-2 Bridge, Masimo, Irvine, California, USA) affixed within the recovery room in approximately 5 min and discharged home. Average resting and dynamic pain scores measured on the 0–10 Numeric Rating Scale were a median of 1 over the first 2 days, subsequently falling to 0. Five patients avoided opioid use entirely, while the remaining two each consumed 5 mg of oxycodone during the first 1–2 postoperative days. After 5 days, the devices were removed at home and discarded.

Conclusions These cases demonstrate that ambulatory percutaneous auricular neuromodulation is feasible and may be an effective analgesic and decreasing or even negating opioid requirements following outpatient surgery. Considering the lack of systemic side effects, serious adverse events, and misuse/dependence/diversion potential, further study with a randomized, controlled trial appears warranted.

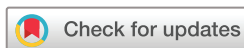INTRODUCTION

The moderate-to-severe pain many patients experience following surgery is often treated with opioids, which are associated with side effects such as nausea, vomiting, sedation, and respiratory depression (and a risk of misuse, dependence, and diversion). Potent site-specific analgesia with fewer side effects may be provided with peripheral nerve blocks. However,

these too have limitations such as requiring an anesthesiologist for administration, a duration of action measured in hours, and rendering the target area/limb insensate. An analgesic alternative with few associated limitations is neuromodulation. Percutaneous leads inserted under ultrasound guidance and subsequently attached to an external pulse generator provide postoperative analgesia and may be administered on an outpatient basis.¹ However, this technique requires physician-level skills, advanced equipment, up to an hour to administer, targets only one nerve or plexus, and is—at least at the time of this writing—often cost prohibitive.²

In contrast, percutaneous auricular neuromodulation may be administered simply by pressing electrodes into the skin anterior to and on the outer ear, followed by stimulation with a wearable pulse generator. The mechanism of action for this modality is complex, multifactorial and remains under investigation.^{3–4} Periauricular innervation has contributions from cranial nerves V (auriculotemporal branch of the mandibular nerve), VII (posterior auricular branch of the facial nerve), IX (glossopharyngeal nerve) and X (auricular branch of the vagus nerve) as well as the occipital and great auricular nerves from the second and third cervical levels.⁵ Stimulation of different anatomic locations results in differing effects, including modulation of serotonergic, noradrenergic, and endorphinergic pathways with associated release of serotonin, norepinephrine, and endogenous opioids such as beta-endorphins.⁶ Vagal stimulation further chemically modulates nociceptive (pain) processing, anxiety, and depression.^{7,8} Many neurotransmitters are influenced, such as increasing gamma-aminobutyric acid which can lead to anxiolysis.⁴ Given the large number of effects auricular stimulation produces, it is unsurprising that it has multiple therapeutic uses, including treating neurological (eg, epilepsy), inflammatory, and cardiovascular disorders; metabolic syndromes; psychiatric symptoms and disorders (eg, anxiety, depression, autism),⁹ as well as multiple pain conditions.⁴

A percutaneous auricular neuromodulation device is currently cleared by the US Food and Drug Administration (FDA) to reduce symptoms associated with opioid withdrawal for up to 5 days (NSS-2 Bridge, Masimo, Irvine, California, USA; figure 1).^{10–12} Three small non-randomized studies



© American Society of Regional Anesthesia & Pain Medicine 2022. Re-use permitted under CC BY-NC. No commercial re-use. Published by BMJ.

To cite: Ilfeld BM, Finneran IV JJ, Dalstrom D, et al. *Reg Anesth Pain Med* Epub ahead of print: [please include Day Month Year]. doi:10.1136/rapm-2022-103777

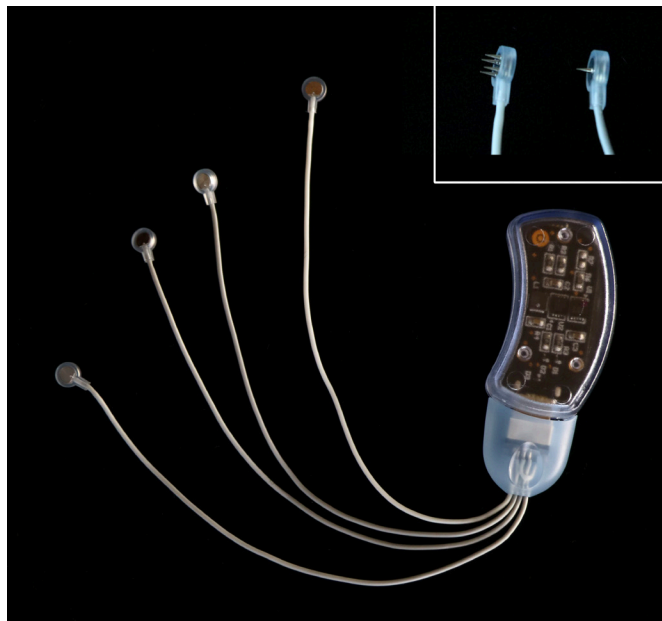

Figure 1 A percutaneous auricular nerve stimulation system (NSS-2 Bridge, Masimo, Irvine, California, USA). Each of the three electrodes has a 2 mm long integrated needle/lead (inset) and the ground electrode has four 2 mm long integrated needles/leads (inset). Used with permission from BMI.

suggest that this device may also provide analgesia in hospitalized patients following abdominal and pelvic surgery.^{13–15} Similarly, the technique was reported in two cases to treat pain following total hip and knee arthroplasty.¹⁶ The device is small, disposable, medication-free, non-surgical, battery-powered, and adhered directly to the skin behind the ear; relatively simple to apply, requiring no additional equipment or advanced training; has few contraindications; lacks systemic side effects and associated serious adverse events; has no potential for misuse, dependence, or diversion; and is a fraction of the cost relative to currently-available ultrasound-guided percutaneous neuromodulation devices.¹⁶

This auricular neuromodulation device therefore may be applied in an ambulatory surgical center and for nearly all outpatient surgeries without the limitations of opioids, peripheral nerve blocks, and ultrasound-guided percutaneous peripheral nerve stimulation devices. And while the published (nonrandomized) controlled studies reported a 56%–75% decrease in opioid requirements using the auricular device to treat pain following major abdominal surgery,^{13–15} it may result in a near-negation of opioid requirements for less-painful ambulatory procedures. However, it remains unknown whether this percutaneous auricular nerve stimulator will provide analgesia following ambulatory orthopedic and breast surgery; and if these patients will accept the device outside of the hospital setting (including home removal).

We now report seven off-label cases to (1) explore the possibility of treating postoperative pain in outpatients with ambulatory percutaneous auricular neuromodulation, (2) help optimize a future study protocol, and (3) estimate the treatment effect to help power a subsequent randomized, controlled pilot study. This manuscript adheres to the applicable Enhancing the QUALity and Transparency Of health Research (EQUATOR) guidelines.

Table 1 Anthropometric patient characteristics

Age (years)	54 (17)
Female sex (#)	5 (71%)
Height (cm)	173 (7)
Weight (kg)	74 (13)
Body mass index (kg/m ²)	25 (3)
Data presented as mean (SD) or number of patients (percentage).	

CASE DESCRIPTION

Following moderately painful orthopedic and breast surgery, seven patients (table 1) were offered, and consented for, postoperative administration of percutaneous auricular neuromodulation (figure 2). The University's Institutional Review Board (University of California San Diego, San Diego, California, USA) waives any review requirements for case reports or short series; but these patients provided both verbal and written consent to receive auricular neuromodulation for the off-label use of postoperative pain control and publish these deidentified case reports and non-identifiable photos.

Patients having orthopedic and breast surgery received ultrasound-guided single-injection popliteal-sciatic and paravertebral nerve blocks, respectively, with ropivacaine 0.5% and epinephrine prior to surgery (table 2). Following surgery in a semirecumbent position within the recovery room, each patient received intravenous fentanyl 25 µg and the application locations were wiped with an alcohol pad and benzoin over the mastoid process for the pulse generator and at the four points of electrode placement (figure 2).¹⁶

The pulse generator was applied posterior and slightly caudad to the preferred ear (contralateral to the side on which the patient slept) with a double-sided adhesive pad which was further secured with a clear adhesive dressing. Each of three electrodes and a ground has a 2 mm long integrated needle(s) (figure 1) and is affixed with a small, round adhesive bandage (figure 2).¹⁶ Specific lead locations on the outer ear were guided with transillumination to optimize effects and avoid placement

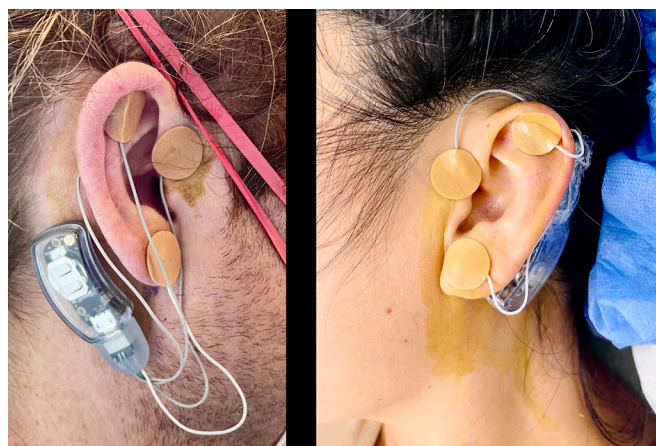

Figure 2 A percutaneous auricular nerve stimulation system (NSS-2 Bridge, Masimo, Irvine, California, USA). The pulse generator is adhered directly to the patient behind the ear over the mastoid process. Leads are placed (1) at the most cephalad portion of the antihelix; (2) immediately cephalo-anterior to the incisura and posterior to the superficial temporal arterial pulse; and (3) on the posterior ear opposite the antihelix at the level of the incisura. The ground electrode is inserted on the anterior side of the lobule (ear lobe). Used with permission from BA.

Table 2 Surgical procedures and NSS-2 Bridge placement

Case	Surgical procedure	Bridge ear	Single-Injection block	Perineural infusion
1	Left: bunionette and hammertoe correction	Left	Left: Popliteal-sciatic	
2	Right: Haglund's excision	Right	Right: Popliteal-sciatic	
3	Right: Haglund's excision	Left	Right: Popliteal-sciatic	
4	Right: hallux interphalangeal joint fusion Left: hammertoe correction	Left	Bilateral: Popliteal-sciatic	Right: Popliteal-sciatic postoperative days 0–3
5	Bilateral: implant removal	Right	Bilateral: Paravertebral	
6	Bilateral: reconstruction revision, fat grafting from abdominal flank liposuction	Left	Bilateral: Paravertebral	
7	Right: Reconstruction with expander and implant Left: mastopexy	Left	Bilateral: Paravertebral	

Single-injection peripheral nerve blocks included ropivacaine 0.5% with epinephrine.
Continuous peripheral nerve block included ropivacaine 0.2% (basal 6 mL/hour, bolus 4 mL, lockout 30 min).

into neurovascular bundles which could cause pain and bleeding. Neurovascular bundles were identified by placing an included pen light against the skin and viewing the opposite side of the ear. For the most cephalad anterior electrode and electrode on the posterior side of the ear, the needles were inserted 1–2 mm away from a neurovascular bundle and never immediately opposite each other.

The first lead was placed at the most cephalad portion of the antihelix by simply pressing the electrode directly into the skin and affixed with an overlying dressing (figure 2).¹⁶ The second electrode was inserted immediately cephalo-anterior to the incisura and posterior to the superficial temporal arterial pulse.¹⁶ The third electrode was inserted on the posterior ear opposite the antihelix at the level of the incisura.¹⁶ The ground electrode with four 2 mm long integrated needles was inserted on the anterior side of the lobule (figure 2, inset), completing the circuit, and beginning the 5-day period of stimulation.¹⁶ All seven patients

tolerated the procedure without wincing or complaint, and total duration for each application was approximately 5 min.¹⁶

Patients were discharged home from the recovery room with a prescription for the synthetic oral opioid oxycodone (5 mg tablets). The one patient with a continuous popliteal-sciatic nerve block received an infusion of ropivacaine 0.2% (6 mL/hour, 4 mL bolus, 30 min lockout, 500 mL reservoir) with a portable infusion pump for the first three postoperative days. Patients were provided with the contact phone numbers of the administering physician and acute pain service and instructed to keep the pulse generators and leads dry with the use of a shower cap when bathing.

Average daily pain at rest and while moving was a median of 0–1 for the first two postoperative days, followed by 0 for subsequent time points as measured using a 0–10 Numeric Rating Scale (figure 3). Maximum pain each day was a median of 3 the first 2 days, 1 the following 2 days, and 0 thereafter (figure 3).

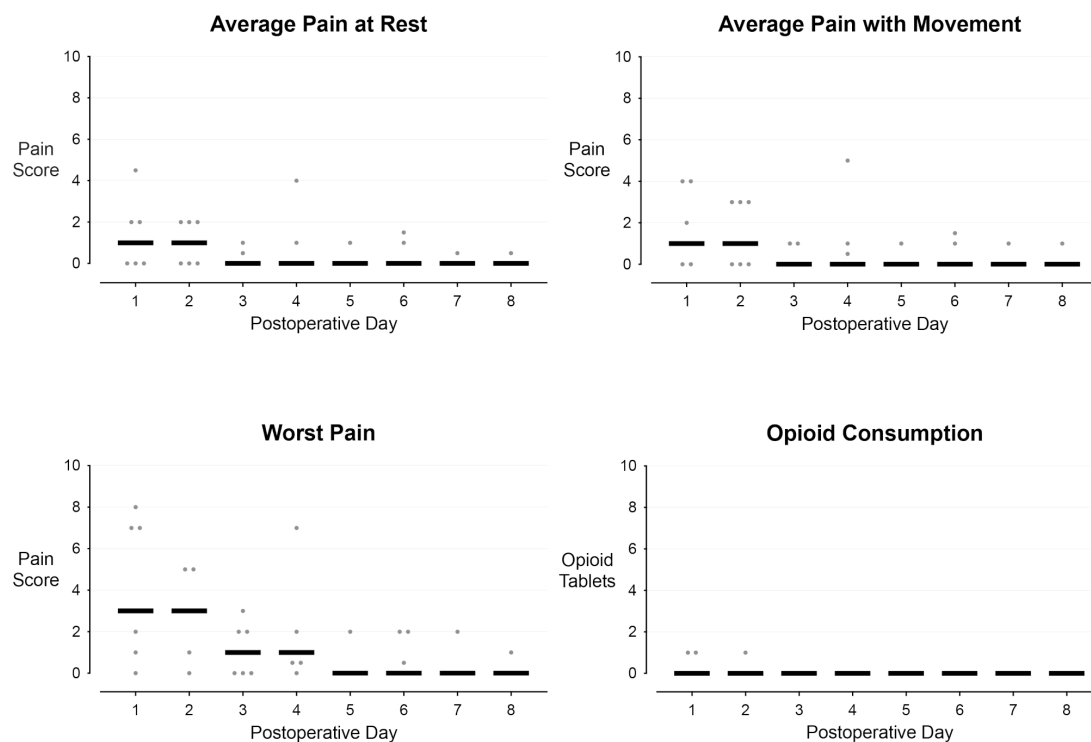


Figure 3 Pain and opioid consumption during outpatient orthopedic and breast surgical procedures with ambulatory percutaneous auricular nerve stimulation for the first 5 postoperative days. Each circle represents one patient, and the median for each time point is denoted with a horizontal line. Pain level was evaluated using a 0–10 Numeric Rating Scale with 0 equivalent to no pain and 10 equivalent to the worst imaginable pain. Each opioid tablet was comprised of 5 mg of the synthetic opioid oxycodone.

Five patients avoided opioid use entirely, while the remaining 2 each consumed 5 mg of oxycodone during the first 1–2 postoperative days (figure 3). All patients perceived various periauricular sensations during the first 24 hours, but rarely following postoperative day 1. The sensations were described as a soft ‘thumping’ or ‘pulsing’ which were never disturbing.

The pulse generators automatically ceased functioning after 120 hours (5 days) and patients or their caretakers then detached the device by first removing the round bandage of the grounding electrode, which extracted the electrode from the patient along with the bandage.¹⁶ The remaining three electrodes were subsequently removed in the same manner, followed by the pulse generator, after which the single-use, disposable device was discarded.¹⁶ No device-related localized irritation, systemic side effects, or complications were identified.¹⁶

DISCUSSION

These cases demonstrate that ambulatory percutaneous auricular neuromodulation affixed in an outpatient surgical facility is feasible and may be an effective analgesic enabling decreased opioid consumption following outpatient surgery considering the relatively low pain scores and opioid use of the current patients to historic patterns at our institution. Given the accumulating evidence of the influence of perioperative prescription opioids on the opioid epidemic, auricular stimulation could have a significant positive impact if our present findings are validated in a future controlled trial: for preoperative opioid-naïve patients, the risk of chronic opioid use 1 year following surgery is 6%.¹⁷ Alarming, 65%–80% of current heroin-dependent users began their addiction by abusing prescription opioids.^{18 19} Furthermore, the number of prescribed opioid tablets is directly correlated with the probability of continuing their use,²⁰ and therefore, a modality allowing the prescription of just a few opioid tablets could prove greatly beneficial to individuals and their communities. Neuromodulation avoids the systemic side effects related to opioid use such as nausea, sedation, and respiratory depression; and it has no potential for misuse, dependence, and diversion.¹⁶ Moreover, the device used in this report is FDA cleared to reduce symptoms associated with opioid withdrawal, which includes anxiety, insomnia, muscle aches, nausea, and vomiting, all of which are frequent following surgery.^{10–12 16}

Other percutaneous auricular neuromodulation devices have been used to provide analgesia following various surgical procedures with various degrees of success, from decreased pain,^{21–23} to no effect,^{24 25} and even increased pain.²⁶ Pulse duration, frequency, amplitude, duty cycle, along with additional parameters such as the number and location of electrodes vary greatly among devices. These parameters determine the properties of the generated electric field. Therefore, differing devices—even if similar in appearance—can have considerably different physiologic effects. This is an inconvenient reality which dramatically decreases generalizability of the results from any one clinical trial to other devices, requiring investigation of each device independent of the others. The pulse generator of the current report uses an integrated 3 V battery, has a load impedance range of 1k–10k Ω with 3.2 V maximum, and provides symmetrical, biphasic stimulation cycles occurring at a frequency of 0.125 Hz with periodic rest.¹⁶

Importantly, multiple studies demonstrate that neurologic effects of auricular stimulation outlast the stimulation itself,²⁷ which is why we chose to follow these seven patients for a total of 8 days.¹⁶ Indeed, the patients of the current report experienced little increased pain and no increased opioid

requirements following removal on postoperative day 5, although this could be due simply to a lack of pain after this time point.

The ideal outpatient analgesic would be applicable for all anatomic locations and patients.¹⁶ The auricular neuromodulation device of the current report has few contraindications listed on its label: (1) use of cardiac pacemakers due to a lack of clinical data to demonstrate safety; (2) hemophilia; and (3) psoriasis vulgaris.¹⁶ In addition, the skin where the leads are applied should be intact. The only reported complications have been minor bleeding at the skin (0.91%) and dermatitis from the adhesive bandages (0.91%).^{12 16} We administered a minimal dose of fentanyl (25 μ g) for our postoperative patients with intravenous lines in situ, but for the pivotal studies with use in reducing the symptoms of opioid withdrawal (n=1207), no analgesic was administered for electrode placement and only two participants had ‘significant’ pain (0.17%).^{12 16}

Once initiated, the stimulator remains functional for 120 hours (5 days) without requiring any intervention—there are no controls or even an on/off switch. In addition to its low health-care provider burden, the device’s low patient burden is reflected in its low weight (5 g) and size (36×16×17 mm).¹⁶

These cases demonstrate that ambulatory percutaneous auricular neuromodulation is feasible and may be an effective analgesic enabling decreased opioid consumption following outpatient surgery. Since (non-randomized) controlled studies report a 56%–75% decrease in opioid requirements using the auricular device to treat pain following major abdominal surgery in hospitalized patients,^{13–15} there is the intriguing possibility of obviating opioid requirements for less-painful ambulatory procedures. Considering its ease of placement, few contraindications, applicability to any anatomic surgical location, low patient/provider burden, lack of systemic side effects and serious adverse events as well as any misuse/dependence/diversion potential, further study with a randomized, controlled trial appears warranted to document and quantify potential analgesic and opioid-sparing benefits.

Collaborators not applicable.

Contributors BMI: identified the intervention, identified and contacted potential patients, followed patients, collected data, wrote the initial manuscript draft, and approved the final draft. JFF: helped develop the intervention pathway, administered the intervention, helped revise the manuscript, and approved the final draft. DD: helped develop the intervention pathway, following patients, helped revise the manuscript, and approved the final draft. AMW: helped develop the intervention pathway, following patients, helped revise the manuscript, and approved the final draft. BA: assisted in patient management, helped revise the manuscript, and approved the final draft. ETS: helped develop the intervention pathway, administered the intervention, helped revise the manuscript, and approved the final draft.

Funding Funding for this project provided by the University California San Diego Department of Anesthesiology (San Diego, California, USA).

Disclaimer The contents of this article are solely the responsibility of the authors and do not necessarily represent the official views of the funding entity. None of the authors has a personal financial interest in this research.

Competing interests The University of California San Diego has received funding and/or product from the following companies for other research studies of the authors: Epimed International (Farmers Branch, Texas, USA), SPR Therapeutics (Cleveland, Ohio, USA), Infutronic (Natick, Massachusetts, USA), and Avanos Medical (Irvine, California, USA).

Patient consent for publication Not applicable.

Provenance and peer review Not commissioned; internally peer reviewed.

Open access This is an open access article distributed in accordance with the Creative Commons Attribution Non Commercial (CC BY-NC 4.0) license, which permits others to distribute, remix, adapt, build upon this work non-commercially, and license their derivative works on different terms, provided the original work is

properly cited, an indication of whether changes were made, and the use is non-commercial. See: <http://creativecommons.org/licenses/by-nc/4.0/>.

ORCID iDs

Brian M Ilfeld <http://orcid.org/0000-0002-6144-3273>

John J Finneran IV <http://orcid.org/0000-0002-0955-155X>

Baharin Abdullah <http://orcid.org/0000-0002-7044-5596>

Engy T Said <http://orcid.org/0000-0002-7897-1670>

REFERENCES

- Ilfeld BM, Plunkett A, Vijjeswarapu AM, et al. Percutaneous peripheral nerve stimulation (neuromodulation) for postoperative pain: a randomized, sham-controlled pilot study. *Anesthesiology* 2021;135:95–110.
- Ilfeld BM, Finneran JJ. Cryoneurolysis and percutaneous peripheral nerve stimulation to treat acute pain. *Anesthesiology* 2020;133:1127–49.
- Kaniusas E, Kampusch S, Tittgemeyer M, et al. Current Directions in the Auricular Vagus Nerve Stimulation I - A Physiological Perspective. *Front Neurosci* 2019;13:854.
- Groves DA, Brown VJ. Vagal nerve stimulation: a review of its applications and potential mechanisms that mediate its clinical effects. *Neurosci Biobehav Rev* 2005;29:493–500.
- Mercante B, Deriu F, Rangon C-M. Auricular neuromodulation: the emerging concept beyond the stimulation of vagus and trigeminal nerves. *Medicines* 2018;5. doi:10.3390/medicines5010010. [Epub ahead of print: 21 01 2018].
- Lockard JS, Congdon WC, DuCharme LL. Feasibility and safety of vagal stimulation in monkey model. *Epilepsia* 1990;31(Suppl 2):S20–6.
- Conway CR, Xiong W. The mechanism of action of vagus nerve stimulation in treatment-resistant depression: current Conceptualizations. *Psychiatr Clin North Am* 2018;41:395–407.
- Beekwilder JP, Beems T. Overview of the clinical applications of vagus nerve stimulation. *J Clin Neurophysiol* 2010;27:130–8.
- Cimpianu C-L, Strube W, Falkai P, et al. Vagus nerve stimulation in psychiatry: a systematic review of the available evidence. *J Neural Transm* 2017;124:145–58.
- Miranda A, Taca A. Neuromodulation with percutaneous electrical nerve field stimulation is associated with reduction in signs and symptoms of opioid withdrawal: a multisite, retrospective assessment. *Am J Drug Alcohol Abuse* 2018;44:56–63.
- Qureshi IS, Datta-Chaudhuri T, Tracey KJ, et al. Auricular neural stimulation as a new non-invasive treatment for opioid detoxification. *Bioelectron Med* 2020;6:7.
- Roberts A, Sithole A, Sedghi M, et al. Minimal adverse effects profile following implantation of periauricular percutaneous electrical nerve field stimulators: a retrospective cohort study. *Med Devices* 2016;9:389–93.
- Chelly JE, Monroe AL, Planinsic RM, et al. Auricular field nerve stimulation using the NSS-2 BRIDGE® device as an alternative to opioids following kidney donor surgery. *J Complement Integr Med* 2021. doi:10.1515/jcim-2021-0208. [Epub ahead of print: 01 Nov 2021].
- Ahmed BH, Courcoulas AP, Monroe AL, et al. Auricular nerve stimulation using the NSS-2 BRIDGE device to reduce opioid requirement following laparoscopic Roux-en-Y gastric bypass. *Surg Obes Relat Dis* 2021;17:2040–6.
- Lim G, LaSorda KR, Monroe AL, et al. Auricular percutaneous nerve field stimulator device as alternative therapy for cesarean delivery analgesia: proof of concept. *Can J Anaesth* 2019;66:1522–3.
- Ilfeld BM, Finneran JJ, Said ET, et al. Percutaneous auricular nerve stimulation (neuromodulation) for the treatment of pain: a proof-of-concept case report using total joint arthroplasty as a surrogate for battlefield trauma. *J Trauma Acute Care Surg* 2022. doi:10.1097/TA.0000000000003706. [Epub ahead of print: 21 May 2022].
- Brummett CM, Waljee JF, Goesling J, et al. New persistent opioid use after minor and major surgical procedures in US adults. *JAMA Surg* 2017;152:e170504.
- Cicero TJ, Ellis MS, Surratt HL, et al. The changing face of heroin use in the United States: a retrospective analysis of the past 50 years. *JAMA Psychiatry* 2014;71:821–6.
- Kharasch ED, Brunt LM. Perioperative opioids and public health. *Anesthesiology* 2016;124:960–5.
- Shah A, Hayes CJ, Martin BC. Characteristics of Initial Prescription Episodes and Likelihood of Long-Term Opioid Use - United States, 2006–2015. *MMWR Morb Mortal Wkly Rep* 2017;66:265–9.
- Sator-Katzenschlager SM, Wölfler MM, Kozek-Langenecker SA, et al. Auricular electroacupuncture as an additional perioperative analgesic method during oocyte aspiration in IVF treatment. *Hum Reprod* 2006;21:2114–20.
- Kager H, Likar R, Jabarzadeh H, et al. Electrical punctual stimulation (P-STIM) with ear acupuncture following tonsillectomy, a randomised, controlled pilot study. *Acute Pain* 2009;11:101–6.
- Likar R, Jabarzadeh H, Kager I, et al. [Electrical point stimulation (P-STIM) via ear acupuncture: a randomized, double-blind, controlled pilot study in patients undergoing laparoscopic nephrectomy]. *Schmerz* 2007;21:154–9.
- Holzer A, Leitgeb U, Spacek A, et al. Auricular acupuncture for postoperative pain after gynecological surgery: a randomized controlled TRAIL. *Minerva Anestesiol* 2011;77:298–304.
- Michalek-Sauberer A, Heinzl H, Sator-Katzenschlager SM, et al. Perioperative auricular electroacupuncture has no effect on pain and analgesic consumption after third molar tooth extraction. *Anesth Analg* 2007;104:542–7.
- Wigram JR, Lewith GT, Machin D, et al. Electroacupuncture for postoperative pain. *Physiotherapy Pract* 1986;2:83–8.
- Sator-Katzenschlager SM, Scharbert G, Kozek-Langenecker SA, et al. The short- and long-term benefit in chronic low back pain through adjuvant electrical versus manual auricular acupuncture. *Anesth Analg* 2004;98:1359–64.