

American Society of Regional Anesthesia and Pain Medicine expert panel recommendations on point-of-care ultrasound education and training for regional anesthesiologists and pain physicians—part II: recommendations

Stephen C Haskins ^{1,2}, Yuriy Bronshteyn,³ Anahi Perlas ⁴, Kariem El-Boghdady ⁵, Joshua Zimmerman,⁶ Marcos Silva,⁴ Karen Boretsky,⁷ Vincent Chan,⁴ Richelle Kruisselbrink,⁸ Melissa Byrne,⁹ Nadia Hernandez,¹⁰ Jan Boublik,¹¹ William Clark Manson ¹², Rosemary Hogg,¹³ Jonathan N Wilkinson,¹⁴ Hari Kalagara,¹⁵ Jemiel Nejim,^{1,2} Davinder Ramsingh ¹⁶, Hariharan Shankar,¹⁷ Antoun Nader,¹⁸ Dmitri Souza,¹⁹ Samer Narouze ¹⁹

For numbered affiliations see end of article.

Correspondence to

Dr Stephen C Haskins, Anesthesiology, Hospital for Special Surgery, New York, NY 10021, USA; haskinss@hss.edu

Received 29 January 2021

Accepted 4 February 2021

ABSTRACT

Point-of-care ultrasound (POCUS) is a critical skill for all regional anesthesiologists and pain physicians to help diagnose relevant complications related to routine practice and guide perioperative management. In an effort to inform the regional anesthesia and pain community as well as address a need for structured education and training, the American Society of Regional Anesthesia and Pain Medicine Society (ASRA) commissioned this narrative review to provide recommendations for POCUS. The recommendations were written by content and educational experts and were approved by the guidelines committee and the Board of Directors of the ASRA. In part II of this two-part series, learning goals and objectives were identified and outlined for achieving competency in the use of POCUS, specifically, airway ultrasound, lung ultrasound, gastric ultrasound, the focus assessment with sonography for trauma exam, and focused cardiac ultrasound, in the perioperative and chronic pain setting. It also discusses barriers to POCUS education and training and proposes a list of educational resources. For each POCUS section, learning goals and specific skills were presented in the Indication, Acquisition, Interpretation, and Medical decision-making framework.

For each POCUS section, learning goals and specific skills are presented in the Indication, Acquisition, Interpretation, and Medical decision-making (I-AIM) framework. We also discuss barriers to POCUS education and training, as well as the educational resources currently available. Ultimately, these task force recommendations define education, training, competency and credentialing criteria to promote the safe and appropriate use of POCUS for the regional anesthesiologist and pain physician. Ultimately, these guidelines should not be considered standard of care but should serve as a framework for educators and learners, given each individual may require more or less POCUS training than described in the document.

METHODS

An expert panel was assembled for this project based on the ASRA guidelines committee and ASRA Board of Directors. The full details of the process have been previously described in part I.¹

Expert panel education and training recommendations

In the past decade, multiple groups have developed anesthesiologist-specific diagnostic POCUS curricula.^{2–4} These curricula have included training in at least the following: ultrasound physics, image interpretation and image acquisition. Technology can also facilitate training. Interactive, computer-based modules can teach ultrasound physics and image interpretation,^{5,6} and image acquisition can be enhanced with ultrasound simulators.⁶ These computer-based modules and ultrasound simulators may decrease the operational costs of running POCUS training programs and increase learners' access and convenience.

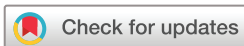While electronic modules could potentially be used to teach the core skillset of *image interpretation*, this Expert Group does NOT believe ultrasound simulators can adequately teach the skillset

INTRODUCTION

As previously described in part I,¹ the American Society of Regional Anesthesia and Pain Medicine (ASRA) guidelines committee and leadership appointed a task force to develop recommendations for education, training and clinical indications for point-of-care ultrasound (POCUS). In this review article, the skills to be discussed are airway ultrasound, lung ultrasound (LUS), gastric ultrasound, the focused assessment with sonography for trauma (FAST) exam, and focused cardiac ultrasound (FoCUS) for the regional anesthesiologist and pain physician.



► <http://dx.doi.org/10.1136/rapm-2021-102560>



© American Society of Regional Anesthesia & Pain Medicine 2021. No commercial re-use. See rights and permissions. Published by BMJ.

To cite: Haskins SC, Bronshteyn Y, Perlas A, et al. *Reg Anesth Pain Med* Epub ahead of print: [please include Day Month Year]. doi:10.1136/rapm-2021-102561

Table 1 Minimum number of supervised studies recommended to achieve competency in specific diagnostic point-of-care ultrasound (POCUS) domains (adapted with permission from a Work Product authored by the American Society of Anesthesiologists' Ad Hoc Committee on POCUS)⁷

POCUS application	Minimum number of supervised studies personally performed and interpreted ("Level 1" studies)	Minimum number of additional supervised studies interpreted but need not be personally performed ("Level 2" studies)	Total number of "Level 1 and 2" studies for competency
Focused airway ultrasound	30	20	50
Focused lung ultrasound	30	20	50
Focused assessment with sonography in trauma	30	20	50
Focused gastric ultrasound	30	20	50
Focused cardiac ultrasound	50	100	150

of *image acquisition* currently. Learners need to scan live models or patients to hone their image acquisition skills. Toward that end, the following is a review of the published literature on this topic, culminating in recommendations regarding minimum training numbers for each organ system. An American Society of Anesthesiologists' Ad Hoc Committee (ASA AHC) on POCUS also recently provided recommendations on this topic,⁷ and the ASRA Expert panel concurs with those recommendations (table 1).

These joint ASA AHC/ASRA Expert Group recommendations distinguish between (1) "studies performed and interpreted" (image acquisition) and (2) "studies interpreted but not necessarily performed"⁷ (image interpretation). These two categories are consistent with guidelines and recommendations from other professional medical societies^{5 8} and allow for image interpretation through computer-based learning. In these recommendations, the two types of training studies will be referred to as "Level 1" and "Level 2" studies, respectively. For supervised studies both interpreted and performed ("Level 1 studies"), learners benefit from directed hands-on supervision for at least the first 5–10 studies. After the learner demonstrates basic image acquisition competency, supervision for both "Level 1" and "Level 2" studies can be done remotely. For example, once a learner demonstrates the ability to obtain adequate images, subsequent "Level 1" training studies can be performed independently and then sent with an accompanying report to a supervisor for feedback. As stated in table 1, competency is not achieved until the learner has completed the combined number of "Level 1" and "Level 2" studies performed and interpreted. The numbers put forth by the expert panel are detailed for each skill in the sections titled "Hands-on Training" and "Minimum Training Standards." The numbers are not considered "standard of care" but are based on the best current evidence available. Once competency is achieved, its maintenance requires lifelong practice and learning to ensure skills are retained.

Assessment of competency in POCUS is recommended by several medical specialties,^{9–14} and often include (1) a knowledge examination using multiple-choice questions and (2) a practical assessment of hands-on skills during a supervised scanning session in addition to a logbook review.⁹ Competency requires an observable ability to integrate multiple learning components such as knowledge, skills, values and attitudes.^{15 16} According to Miller's hierarchical framework for assessing physicians,¹⁷ the foundational level is factual knowledge or "knowing." The second level is "knowing how," which incorporates data judgment to make an informed decision about patient management. The third level of knowledge is "showing how," which includes clinical judgment and practical skills. The final level of knowledge is to demonstrate the skills and knowledge with actual patients "doing." The assessment of this level of behavior

remains the most challenging to accomplish reliably and accurately.^{16 17} Table 2 contains a summary of the recommendations.

For both learners and supervisors, this ASRA group encourages communication of diagnostic ultrasound findings through the I-AIM framework, and each subject with be framed as such.¹⁸ In summary, for each of the following POCUS skills discussed, the expert panel recommends:

Summary of training recommendations for each POCUS skill

- ▶ The I-AIM model is used as the framework for didactic and hands-on training and to guide competency assessment.
- ▶ Didactic curricula may include in-class or online components.
- ▶ Training should include hands-on sessions on live models with normal anatomy and sonoanatomy for each particular skill to aid in image acquisition and familiarity with normal anatomy. Pathology can be reviewed either by a simulator, scanning patients with known pathology, or reviewing clinical cases.
- ▶ Curriculum content should be reviewed on an ongoing basis.
- ▶ Further research is encouraged to investigate the optimal training methodologies, approach to competency assessment, and learning curves in an anesthesiology and pain clinical environment.
- ▶ Refer to table 1 for the minimum number of supervised studies recommended to achieve competency in each of the specific diagnostic POCUS domains.
- ▶ Note: tables 3–7 provide a summary for each skill in the I-AIM format. Online supplemental file 1—part II (I-AIM Checklists for POCUS Skills) provides a printable checklist for educators to help structure education/training and track learners' process.

Airway

Due to the broad indications for airway ultrasound, there is no consistent structure to training content in published studies.^{19–24} However, the fundamental knowledge required for all applications is understanding the sonoanatomy of the airway and surrounding structures. Therefore, airway ultrasound training curricula should follow the I-AIM framework, as described in other POCUS applications.^{18 25 26} The I-AIM framework (table 3) includes understanding the following: the indications for airway ultrasound (Indication); the relevant physics and how to optimize scanning and image acquisition (Acquisition); the diagnostic interpretation of relevant anatomical structures, including, but not limited to, the hyoid bone, thyroid cartilage, vocal cords, cricothyroid membrane, cricoid cartilage, tracheal rings, esophagus, and their relationship to surrounding and surface landmarks (Interpretation); the procedural confirmation of esophageal and tracheal placement of nasogastric and

Table 2 Summary of expert panel recommendations incorporating Miller's hierarchical framework for assessing physicians with the Indication, Acquisition, Interpretation, and Medical decision-making algorithm

Bedside POCUS		Content	Training tools	Assessment
Indication	Knowing Theoretical knowledge	Physics Knobology Relevant sonoanatomy Artifacts	Class-based lectures Web-based lectures Required reading Online resources Podcast Videos	Pre/Post-test (to ensure knowledge acquisition) MCQs SAQs
Acquisition	Knowing how Image acquisition	Ergonomics Probe selection Image generation Image optimization	Healthy volunteers Pathology Simulator Standardize live pathology Animal models Virtual reality	Validated performance test Image interpretation
Interpretation	Showing how Clinical integration +practical skills	Systematic approach Pitfalls Limitations Troubleshooting	Direct supervision on patients Workshops Small group discussion Case review Virtual reality	Portfolio collection Image interpretation
Medical decision-making	Doing Decision-making	Algorithms Clinical integration Medical implications Interventions	Direct supervision on patients Simulators (for select pathology)	Direct observation using validated assessment tools

MCQs, multiple-choice questions; POCUS, point-of-care ultrasound; SAQs, short answer questions.

tracheal tubes (Interpretation); utilizing the imaging to aid clinical decision-making for cricothyroid puncture, cricoid pressure, nasogastric and tracheal tubes (Medical management).

Knowledge acquisition

Didactic content for airway ultrasound is available through the reading of anatomical material, lecture-based sessions, electronic/online content,²⁷ cadaveric training, and, finally, bedside practice. Online resources, small group case-based image analysis, coupled

with hands-on training using cadavers, volunteers, or patients in a structured format, can further develop airway ultrasound skills.^{3 28} Multiple learning modalities updated on an ongoing basis within a structured educational program will incorporate best evidence and practice for this relatively new skill.

Hands-on training

While literature across several medical specialties supports airway ultrasound use, it is not a mandatory part of residency

Table 3 The education and training goals in airway point-of-care ultrasound (POCUS) following an Indication, Acquisition, Interpretation, and Medical decision-making framework

Education/training goals in airway POCUS		Optimal learning tool
Indications and background knowledge (may be pre-existing)	Basic physics of ultrasound Anatomy/sonoanatomy of the Airway Indications of airway POCUS: Aid in the location of: ▶ The cricothyroid membrane ▶ The cricoid cartilage ▶ The tracheal rings Confirmation of: ▶ Orogastric or nasogastric tube placement ▶ Correct endotracheal tube placement	Didactics
Image acquisition	Ergonomics Transducer selection Scan in transverse and sagittal planes Patient positioned with the neck extended Identify relevant anatomy ▶ Thyroid cartilage ▶ Vocal cords ▶ Cricothyroid membrane ▶ Cricoid cartilage ▶ Hyoid ▶ Tracheal rings ▶ Esophagus ▶ Thyroid gland ▶ Surrounding vasculature	Hands on training
Image interpretation	Locate and identify cricothyroid membrane Locate and identify cricoid cartilage Locate and identify tracheal rings Confirmation of the esophageal location of orogastric or nasogastric tube Confirmation of intratracheal and excluding esophageal tracheal tube placement	Hands on training
Medical decision-making	Image the cricothyroid membrane in longitudinal and transverse planes and mark the skin for the correct location of emergent cricothyrotomy Determine and mark the skin for the correct location of cricoid force (pressure) Determine the safe utilization of an orogastric or nasogastric tube for gastric decompression or feeding Determine the safe utilization of a tracheal tube for ventilation	Hands on training Clinical case discussions

.POCUS, point-of-care ultrasound.

Table 4 The education and training goals for point-of-care lung ultrasound (LUS) following an Indication, Acquisition, Interpretation, and Medical decision-making framework

Lung ultrasound assessment		Preferred learning tool																																				
Background knowledge	Basic physics of ultrasound Basic knobology B-mode, M-mode Anatomy/sonoanatomy of the thoracoabdominal region	Didactics																																				
Indication	Indications of LUS Pneumothorax Effusions/blood Diaphragmatic paresis Interstitial syndrome Limitations and pitfalls Previous thoracic surgery (pneumectomy, pleurodesis) Severe pre-existing lung disease (bullae, pulmonary fibrosis, septations, emphysema), lung contusion/consolidation Small effusions, intraperitoneal fluid, loculated/complex collections Mechanical ventilation, apnea, ascites, subphrenic fluid accumulation	Didactics																																				
Acquisition	Optimize machine ergonomics Transducer selection: resolution versus penetration Recognize the effect of gravity on the location of air/fluid Identify relevant anatomy (ribs, diaphragm, pleural line, liver, spine)	Hands on training																																				
	<table border="0"> <tr> <td>Pneumothorax</td> <td>Effusion</td> <td>Diaphragm</td> <td></td> </tr> <tr> <td>Linear probe</td> <td>Curvilinear probe</td> <td>Linear/curvilinear probe</td> <td>Hands on training</td> </tr> <tr> <td>Least dependent part of the chest</td> <td>The posterior axillary line at the level of the xiphoid</td> <td>The mid-axillary line at the eighth–ninth ICS or Midclavicular/anterior axillary line at the subcostal region</td> <td></td> </tr> <tr> <td>Identify: Superior and inferior ribs and their shadows</td> <td>Identify: diaphragm anterior chest wall</td> <td></td> <td></td> </tr> <tr> <td>Pleural line</td> <td>Lung parenchyma</td> <td></td> <td></td> </tr> </table>	Pneumothorax	Effusion	Diaphragm		Linear probe	Curvilinear probe	Linear/curvilinear probe	Hands on training	Least dependent part of the chest	The posterior axillary line at the level of the xiphoid	The mid-axillary line at the eighth–ninth ICS or Midclavicular/anterior axillary line at the subcostal region		Identify: Superior and inferior ribs and their shadows	Identify: diaphragm anterior chest wall			Pleural line	Lung parenchyma																			
Pneumothorax	Effusion	Diaphragm																																				
Linear probe	Curvilinear probe	Linear/curvilinear probe	Hands on training																																			
Least dependent part of the chest	The posterior axillary line at the level of the xiphoid	The mid-axillary line at the eighth–ninth ICS or Midclavicular/anterior axillary line at the subcostal region																																				
Identify: Superior and inferior ribs and their shadows	Identify: diaphragm anterior chest wall																																					
Pleural line	Lung parenchyma																																					
Interpretation	<table border="0"> <tr> <td>Highly likely</td> <td>Confirmation</td> <td>Confirmation</td> <td>Hands on training</td> </tr> <tr> <td>Lung point</td> <td>Anechoic collection cephalad to the diaphragm</td> <td>$\Delta t_{di} < 20\%$</td> <td>Clinical case discussions</td> </tr> <tr> <td>Likely</td> <td>Spine sign</td> <td>Excursion less than 1.8 cm during quiet breathing or less than 4.8 cm during deep breathing</td> <td></td> </tr> <tr> <td>Absence of lung sliding and A-line pattern</td> <td>Sinusoid sign</td> <td>Paradoxical movement on inspiration (towards probe)</td> <td></td> </tr> <tr> <td>Barcode sign</td> <td>Excluded</td> <td></td> <td></td> </tr> <tr> <td>Excluded</td> <td>Curtain sign</td> <td></td> <td></td> </tr> <tr> <td>Vertical artifacts (B-lines, comet tail)</td> <td></td> <td></td> <td></td> </tr> <tr> <td>Lung sliding/pulse</td> <td></td> <td></td> <td></td> </tr> <tr> <td>Seashore sign</td> <td></td> <td></td> <td></td> </tr> </table>	Highly likely	Confirmation	Confirmation	Hands on training	Lung point	Anechoic collection cephalad to the diaphragm	$\Delta t_{di} < 20\%$	Clinical case discussions	Likely	Spine sign	Excursion less than 1.8 cm during quiet breathing or less than 4.8 cm during deep breathing		Absence of lung sliding and A-line pattern	Sinusoid sign	Paradoxical movement on inspiration (towards probe)		Barcode sign	Excluded			Excluded	Curtain sign			Vertical artifacts (B-lines, comet tail)				Lung sliding/pulse				Seashore sign				
Highly likely	Confirmation	Confirmation	Hands on training																																			
Lung point	Anechoic collection cephalad to the diaphragm	$\Delta t_{di} < 20\%$	Clinical case discussions																																			
Likely	Spine sign	Excursion less than 1.8 cm during quiet breathing or less than 4.8 cm during deep breathing																																				
Absence of lung sliding and A-line pattern	Sinusoid sign	Paradoxical movement on inspiration (towards probe)																																				
Barcode sign	Excluded																																					
Excluded	Curtain sign																																					
Vertical artifacts (B-lines, comet tail)																																						
Lung sliding/pulse																																						
Seashore sign																																						
Medical decision-making	Ability to integrate exam findings to patient management Consider limitations and pitfalls Consider the urgency and severity of the symptoms	Clinical case discussions																																				
	Needle decompression versus chest tube versus pigtail	Observation versus chest-tube versus thoracotomy	Supportive measurements NIMV versus intubation																																			

.B-Mode, brightness mode; ICS, intercostal space; LUS, Lung ultrasound; M-Mode, motion mode; NIMV, non-invasive mechanical ventilation; Δt_{di} , change in diaphragm thickness between end-expiration and end-inspiration.

training in any specialty. Neither general surgery nor otolaryngology residencies require airway sonography in their training, with otolaryngology requiring “20 Airways” as a graduation requirement. Similarly, while POCUS is incorporated into anesthesiology residency,²⁹ there is no specific airway sonography requirement at this point. Emergency medicine is the only exception where airway ultrasound can be credited as part of the required 150 bedside ultrasound exams.³⁰

The American Academy of Otolaryngology-Head and Neck Surgery and the American Institute of Ultrasound in Medicine (AIUM) created both practice³¹ and training guidelines³² for “physicians who evaluate and interpret diagnostic ultrasound examinations of the neck,” suggesting 100 exams within 36 months as well as 15 continuing medical education (CME) credits. This recommendation is in line with the AIUM Training guidelines for POCUS,³³ which suggest 150 US exams total (with a minimum of 25 per focused area), as well as 36 hours of CME AMA Category 1 credits that are based on the American College of Emergency Physicians (ACEP) guidelines.³⁴

Data suggest that competency in ultrasound identification of the cricothyroid membrane can be achieved with limited training, such as an online tutorial or a 2 hours classroom tutorial when combined with hands-on training sessions of at least 20 airway exams,³⁵ or 10 exams to be able to distinguish endotracheal and esophageal intubation.²³

Minimum training standards

One study has evaluated the minimum number of studies required to achieve competency in anesthesiology-relevant airway ultrasound. In this study, six anesthesiology trainees (four residents and two fellows) were given a 2 hours training session centered on identifying neck landmarks and the cricothyroid membrane.³⁵ One to 2 weeks later, each trainee was tasked to identify the cricothyroid membrane with ultrasound on 20 healthy volunteers. The authors defined “competency” a priori as a 90% success rate. Four of the six trainees achieved competency within 20 attempts, while the remaining two achieved success rates of 75% and 80%. Three-month retention on five

Table 5 The education and training goals for the focused assessment with sonography for trauma (FAST) exam following an Indication, Acquisition, Interpretation, and Medical decision-making framework

Education/training goals for the FAST exam		Preferred learning tool
Indications and background knowledge (may be pre-existing)	Basic physics of ultrasound Anatomy/sonoanatomy of the upper abdomen Indications for FAST exam Hypotensive trauma patient Hypotensive postoperative gynecological/obstetric patient (FASO) Re-evaluation of a trauma patient Abdominal pain following hip arthroscopy A patient who is critically ill in PACU	Didactics
Image acquisition	Ergonomics Transducer selection Evaluate all four views of the FAST exam RUQ (Morison's pouch) LUQ (perisplenic space including splenorenal interface) Pelvis views (longitudinal and transverse) Subcostal cardiac views Patient positioning Trendelenburg position can improve the sensitivity of RUQ/LUQ views Reverse-Trendelenburg position can improve the sensitivity of pelvic views	Hands on training
Image interpretation	Scan for evidence of free fluid in Abdomen (RUQ/LUQ) Pelvis Pericardium	Hands on training
Medical decision-making	Trauma assessment: Consider additional imaging if the patient is stable Proceed to the operating room for laparotomy if positive Intra-abdominal fluid extravasation (IAFE): Consider inpatient management for IAFE Postoperative shock: Consider returning to the operating room for surgical exploration Postprocedural shock: A concern of bleeding following interventional pain procedure and consider surgical consultation	Clinical case discussions

FASO, focused assessment with sonography for obstetrics; IVC, inferior vena cava; LUQ, left upper quadrant; PACU, postanesthesia care unit; RUQ, right upper quadrant.

normal volunteers demonstrated a combined mean success rate of 87% (compared with 94% initially). This study suggests that the minimum number of training studies required to locate the cricothyroid membrane with ultrasound consistently is *at least* 20.

However, this study has at least two important limitations. First, the small sample size limits generalizability. Second, identifying the cricothyroid membrane is only one of several airway ultrasound applications of relevance to anesthesiologists. At a minimum, airway ultrasound can also be used to determine endotracheal tube location and screen for vocal cord paralysis during stridor evaluation.³⁶

For these reasons, the minimum number of training studies to achieve competency in all of the anesthesiologist-relevant airway ultrasound applications is likely higher than 20. Based on learning curve data from other organ systems (see below) and consistent with the recommendations of the ASA AHC,⁷ this ASRA Expert Group supports the following minimum supervised training numbers for airway ultrasound-naïve anesthesiologists: 30 “Level 1” airway exams and 20 “Level 2” airway exams (table 1).

Lung ultrasound

Existing data make it challenging to provide standardized recommendations for education and certification in LUS. The heterogeneity in study design, low level of evidence, lack of validated assessment tools and high risk of bias is the source of this challenge. However,³⁷ as is the case with most POCUS curricula, a stepwise approach consisting of knowledge followed by skills

acquisition can build competency through practice. Nevertheless, a variety of didactic modalities exist,⁹ and an LUS curriculum should follow the I-AIM framework (table 4).¹⁸

Knowledge acquisition

Soon *et al*³⁸ found that web-based LUS teaching is as effective as traditional classroom didactics in improving the novice pediatric learners' knowledge and skillset in image acquisition and interpretation of pneumothorax and pleural effusion. Likewise, Edrich *et al*³⁹ found both training methods to be equally effective in training anesthesiologists to diagnose pneumothorax.

A model/simulation-based lecture that included student practice on a human model and simulation mannequin was more effective than a traditional didactic 90 min one-on-one lecture in teaching the POCUS skills required to assess cardiopulmonary function, volume status and severe thoracic/abdominal injuries.⁴⁰

Hands-on skill acquisition

Self-directed learning (online modules, reading material) or classroom learning should precede hands-on training on volunteers. Image acquisition through supervised scanning on volunteers or simulation can create a basic image portfolio with relevant thoracic sonoanatomy and lung artifacts and signs. Image interpretation can be reinforced through supervised case discussions, self-directed online case review and image interpretation of a portfolio that includes normal and pathologic studies. However, teaching methods that adopt a small-group format, video-clip examples and hands-on scanning sessions are often considered

Table 6 The education and training goals for point-of-care gastric ultrasound (POCUS) following an Indication, Acquisition, Interpretation, and Medical decision-making framework

Education/training goals in gastric POCUS	Preferred learning tool
Indications and background knowledge (may be pre-existing) Basic physics of ultrasound Anatomy/sonoanatomy of the upper abdomen Indications of gastric POCUS Unclear history and/or unknown fasting status Urgent surgery Risk factors for delayed gastric emptying Limitations and pitfalls Previous gastric surgery Large hiatal hernia	Didactics
Image acquisition Ergonomics Transducer selection Scan in a sagittal plane in the epigastrium Recognize the importance of the right lateral decubitus position Identify relevant anatomy (liver, pancreas, aorta, spine) Consistently identify the gastric antrum, body and pylorus	Hands on training
Image interpretation Qualitative classification of gastric content: Empty (no content) Clear fluid (3-point grading system) Solid (early/late)/thick fluid Quantitative evaluation of clear fluid Estimate volume based on a CSA of the antrum in the RLD	Hands on training
Medical decision-making Ability to integrate exam findings to patient management If no content or low fluid volume (≤ 1.5 mL/kg) Consistent with an "empty stomach" Proceed with the case No special aspiration precautions indicated If solid content or high fluid volume (> 1.5 mL/kg) Consistent with a "full stomach" Consider postponing if elective with recent intake If need to proceed, then use aspiration prophylaxis (eg, awake patient or tracheal intubation, rapid sequence induction) Unclear/equivocal imaging Manage based on available clinical information and local policies regarding fasting guidelines	Clinical case discussions

Adapted from Perlas *et al*, *Br J Anaesth* 2016.²⁶

CSA, cross-sectional area of the gastric antrum in the right lateral decubitus; POCUS, point-of-care ultrasound; RLD, right lateral decubitus position.

most effective.⁴¹ Although LUS is easy to learn, adequate step-wise training and performance are critical for accurate clinical diagnosis and to prevent image misinterpretation leading to diagnostic errors that could delay appropriate interventions.⁴²

Minimum training recommendations

Three published studies have evaluated the minimum number of training studies required to achieve competency in LUS. Blehar *et al* analyzed 52 408 ultrasound examinations performed by Emergency Medicine residents, and ultrasound-naïve attendings at a single academic department over 5 years.⁴³ Seven thousand seven hundred thirteen LUS exams performed by 97 ultrasound learners were assigned a binary score for (1) image quality (adequate vs inadequate) and (2) learner's interpretation of whether the images showed a pneumothorax (accurate vs inaccurate). A plateau of the learning curve (decrease slope $> 25\%$) occurred at 39 exams for image acquisition and 60 for image interpretation.

Millington *et al* studied 10 emergency medicine and critical care trainees asked to performed and interpreted 50 LUS exams. Then, each study was rated by a pair of experts for (1) image quality on a 0–5 scale and (2) whether or not specific pathologies (pneumothorax, interstitial syndrome, consolidation, and pleural effusion) were present, absent or indeterminate. Learner improvement occurred during the first 25–30 practice studies, with slower progression after that.

Finally, Arbelot *et al* conducted a multicenter study on ultrasound-naïve healthcare providers (residents, attendings and respiratory therapists) at 10 centers across three continents.⁴⁴ To complete the study, providers needed to perform a protocolized 12-view exam on at least 25 patients and categorize the findings in each of the 12 lung regions on a 1–5 point scale of lung aeration: "1" representing normal aeration; "5" representing lung consolidation; and "2"–"4" representing intermediate states). One hundred providers completed the study, interpreting a total of 7330 lung regions compared against the gold standard of evaluation by a local LUS expert. Analysis of the data showed that learner accuracy reached 93% after 30 exams.

These three studies support recommendations from professional medical societies. The ACEP recommends 25–50 "Level 1" LUS examinations to achieve competency.⁴⁵ The Society of Critical Care Medicine (SCCM) recommends 20 "Level 1" LUS exams and 10 "Level 2" exams.⁸ The Canadian Critical Care Society (CCCS) recommends trainees complete 20 "Level 1" LUS exams.¹³ A recent survey showed that only 7 out of 25 countries had national LUS training programs with defined competency with significant variation in training requirements and assessments. The number of scans required for LUS training ranged from 20 to 100,⁴⁶ despite most novice learners achieving a flat learning curve after 50 LUS exams.⁴⁷ Of note, with daily performance, the learning curve for diagnosing pleural effusion, lung consolidation, and an alveolar-interstitial syndrome

Table 7 The education and training goals for focused cardiac ultrasound (FoCUS) following an Indication, Acquisition, Interpretation, and Medical decision-making framework

Education/training goals in FoCUS		Preferred learning tool
Indications and background knowledge (may be pre-existing)	Basic physics of ultrasound Cardiac anatomy/sonoanatomy Indications of FoCUS Hemodynamic instability or undifferentiated shock Cardiac arrest Pericardial effusion/tamponade: signs and symptoms Heart failure: signs and symptoms High cardiac risk patients Adjunct to physical examination Limitations and pitfalls Experience and skill set of performing physician No quantifiable data Functionality of equipment	Didactics
Image acquisition	Ergonomics Transducer selection Patient positioning to optimize views Practice performing FoCUS views: Parasternal long axis Parasternal short axis Apical 4-chamber view Subcostal 4 chamber Subcostal inferior vena cava	Hands on training
Image interpretation	Qualitative assessment of: Ventricular dimensions and systolic function Volume status/responsiveness Pericardial effusion/tamponade Gross anatomical abnormalities Gross signs of chronic heart disease	Hands on training Clinical case discussions
Medical decision-making	Ability to integrate exam findings to patient management Evaluate for and determine treatment for the following pathology Local anesthetic systemic toxicity Aortic stenosis Hypovolemia Massive pulmonary embolism Pericardial effusion/tamponade Gross ventricular failure	Clinical case discussions

is less than 6 weeks; however, diagnosing pneumothorax is more challenging.⁴⁸

Based on the professional society recommendations and studies, our expert panel recommends 30 “Level 1” LUS exams and 20 “Level 2” LUS exams to attain competency (table 1).⁷

Focused assessment with sonography for trauma exam

Education and training requirements for the FAST exam are well documented in the emergency medicine literature, but less so in anesthesiology. Therefore, a reasonable approach is to follow the emergency medicine guidelines on education and training for the FAST exam.⁴⁵ Didactic training for the FAST exam may be online or in-person but should use the I-AIM format (table 5). Hands-on training should be performed in conjunction with didactic education. Hands-on training may be performed with human models or simulators. Following didactic and hands-on training, an expert should review each of these training (“Level 1”) exams for accurate image acquisition and interpretation. Review of videos and cases (“Level 2”) can supplement didactic and hands-on training after adequate “Level 1” exams are performed. Methods for the individualized evaluation include direct supervision by experts, image review, ongoing quality assessment, or structured knowledge, and clinical assessments such as the Observed Structured Clinical Examination (OSCE).^{11 49}

Minimum training recommendations

Four studies have attempted to measure the learning curve for FAST exam image acquisition and/or interpretation. Gracias *et al* compared prior FAST experience with diagnostic accuracy when grouping learners into minimal (<30 patient examinations), moderate (30-100), or extensive (>100) experience.⁵⁰ The authors found that FAST exam accuracy increased with experience and that the learning curve began to flatten out at 30–100 exams. Shokoohi *et al* conducted a single-center, observational study of 304 FAST exams performed by 22 first-year and second-year medical students⁵¹ grouped based on the number of exams performed (10–19, 20–29 or >30 scans). The authors found that after completion of at least 30 prior exams, at least 80% of the learners’ images were adequate for the four FAST views. Blehar *et al* analyzed 12 963 FAST exams performed and interpreted by 99 Emergency Medicine-trained ultrasound learners.⁴³ The authors found that the learning curve plateaued for image acquisition at 57 exams. Additionally, after 50 FAST exams, learners’ interpretation achieved a sensitivity of 80% and a specificity of 96%.

Finally, Jang *et al* analyzed 2223 FAST exams performed by 85 Emergency Medicine residents and attendings at a single institution. The authors found that image acquisition and interpretation improved significantly following 10 exams, with misinterpretation of findings approaching 0% after >50 exams performed.

These studies support recommendations from professional medical societies. ACEP recommends that emergency medicine ultrasound trainees perform and interpret 25–50 supervised FAST examinations to achieve competency.⁴⁵ SCCM recommendations state (1) 20 “Level 1” FAST exams and (2) 10 “Level 2” FAST exams.⁸ CCCS recommends that trainees complete 10 “Level 1” FAST exams.¹³ Based on these professional medical society recommendations and the learning curve studies, we recommend 30 “Level 1” FAST exams and 20 “Level 2” FAST exams (table 1).⁷

Gastric ultrasound

Gastric ultrasound is one of the most recently developed POCUS applications with limited literature on training and competency compared with more established POCUS applications. Therefore, these recommendations are derived from the existing literature and the expert opinion of clinical investigators involved in the study, clinical application and training of gastric sonography for the past decade. An I-AIM framework is very well suited for the teaching and learning of POCUS and to guide competency assessment (table 6).^{25 26} Protocol-guided ultrasound examinations ensure consistency, efficient and reliable image acquisition, and accurate diagnosis and documentation.⁵² Training in a POCUS skill typically includes three components: (1) didactics, (2) hands-on training and (3) assessment of competency. This training has been called the three-step mastery-learning approach by Pieterse *et al*.³⁷

Knowledge acquisition

Didactic content should be structured within the categories of the I-AIM model.²⁶ Curricula should include the clinical indications based on current evidence (Indication)^{26 53}; the mechanics and relevant ultrasound physics for scanning and image acquisition (Acquisition)⁵⁴; the anatomy, the performance, expected findings, potential incidental findings, and limitations/potential pitfalls of a qualitative⁵⁴ and quantitative⁵⁵ examination (Interpretation)^{55–58}; algorithms for the application of clinical findings, whether definitive or equivocal (Medical management)⁵⁹; institutional expectations for documentation⁵⁹; and a review of clinical case examples to facilitate knowledge comprehension, integration and translation into the clinical arena.

Didactic content can be acquired using various modalities, including required readings, short lectures, presentations and online resources.⁶⁰ Online resources allow for accessibility and flexibility, and standardization of content, delivery and assessment.^{37 61–63} A comprehensive website has been developed to deliver the didactic knowledge base for a gastric ultrasound and is freely accessible online at gastricultrasound.org.^{3 28} Small group, case-based image review sessions can encourage thoughtful discussion and debate, which aids content retention.^{3 28} When possible, combining didactic and hands-on learning is more effective than didactic learning alone.^{3 40} Most importantly, longitudinal exposure and formal curricula are required for achieving and maintaining competency.^{4 49 64 65} As such, we recommend that educational content be reviewed regularly as questions arise and the literature evolves.

Hands-on skill acquisition

As mentioned, the combination of didactic and hands-on learning optimizes the retention of new material.⁶³ Initial demonstration should be performed by an expert to highlight proper probe technique and ergonomics. We recommend that training be commenced on live human models with prescribed

oral intake following an 8 hours fasting period to systematically appreciate the characteristics of different types of gastric content (nothing, clear fluids, thick fluids or solids).^{54 66} The hands-on training should include at least one way of assessing the volume of clear fluid, either by using a 3-point grading system previously referred to or by estimating gastric volume based on a CSA of the antrum.

Compared with other POCUS applications, gastric ultrasound is unique in that all potential sonographic findings (ie, all types of antral contents) can be illustrated in healthy volunteer models. Collaborative, interprofessional teaching by a local abdominal sonographer or radiologist can be utilized where an anesthesiologist expert in gastric ultrasound is not available.^{67–69} The hands-on acquisition should subsequently be practiced with supervision in the clinical setting while incorporating the I-AIM framework.²⁶ Exposure to subjects reflective of clinicians’ practice demographics (eg, obstetrics, bariatric, and pediatric patients) is encouraged.

Simulation is not conducive to learning gastric sonography skills, as it is difficult to reproduce many of the technical and anatomic subtleties. These include the varying appearance of the empty antrum among different patients (eg, shape, echogenicity of the walls); the changing relationship between the gastric antrum and other small bowel loops; the dynamic nature of air content in the antrum; the variability in the transverse colon position, and the irregular peristalsis. The ergonomics of scanning in the right lateral decubitus position position, unique to gastric sonography, are also difficult to reproduce on a simulator. Also, the fact that all gastric ultrasound findings can be easily demonstrated on healthy subjects makes simulation seem unnecessary for this particular skill.

Although a minimum number of exams is recommended (table 1), as with all POCUS skills, the number of exams alone does not predict clinical competency,^{6 66 70} and a greater number of exams performed does not mean higher quality.^{43 71} Thus, in addition to numerical benchmarks, the competency assessment must include observation of learner skills,^{11 72–74} ideally guided by a validated assessment tool.^{3 4 6 11 28 37 40 43 49 58 60–66 68–79} Since a validated scoring tool does not yet exist for gastric ultrasound, we recommend adopting a structured assessment checklist from another ultrasound application such as the one developed by Skaarup *et al* for LUS.⁸⁰ The assessment should include: indication, systematic approach, technical skills, identification and differentiation of normal anatomy and antral contents, documenting and reporting, and diagnostic conclusion.⁸⁰ For maintenance of competency and ongoing quality assurance (QA), gastric ultrasound is distinct from other POCUS applications. It can be performed on healthy individuals, and one does not need formal radiographic studies to determine accuracy. Instead, the findings need only be compared with the known oral intake history if available, or in some instances of a full stomach, by the contents found after insertion of an NG tube (where clinically appropriate) in the clinical arena.⁶³ Finally, we recommend that future studies investigate the optimal training methodologies, approach to competency assessment, and learning curves of gastric ultrasound to ensure that patients receive gastric ultrasound assessments of the highest caliber.

Minimum training recommendations

One study has evaluated the minimum number of examinations required to achieve competency in gastric ultrasound.⁶⁶ In this study, six gastric ultrasound naïve anesthesiologists (fellow or staff level) were given an extensive curriculum and were then

asked to perform 30 ultrasound examinations on standardized patients. The learners were blinded to the SPs' gastric contents, and interpretations of the images were recorded and analyzed. An average of 24 examinations was required to reach a 90% success rate (competency), and the authors estimated that it would take an average of 33 examinations to achieve a 95% success rate. Although the sample size was small, the data are generally consistent with other POCUS domains' measured learning curves.^{43 44} Based on these data, the ASRA Expert Group proposes the following minimum training numbers for gastric ultrasound: 30 "Level 1" exams and 20 "Level 2" exams (table 1).

Focused cardiac ultrasound

By definition, FoCUS is a limited, qualitative, 2-dimensional exam utilizing 5–6 views to identify obvious pathology.⁸¹ A FoCUS exam is often performed by a frontline physician such as an anesthesiologist and is distinctly different from a transthoracic echocardiogram (TTE). TTE is a quantitative exam of the heart using advanced techniques (2-D+color/spectral Doppler) performed by someone with comprehensive training in transthoracic cardiac image acquisition and interpreted by someone with comprehensive training in cardiac ultrasound image interpretation (typically a cardiologist specialized in echocardiography).⁸² Although, FoCUS is not as complex as TTE, it is arguably the most challenging POCUS skill to learn. However, there are still significant data to suggest that it can be learned relatively quickly to diagnose a variety of cardiovascular abnormalities, such as aortic stenosis, even for providers with limited training.^{82 83} Novices with limited training (50 exams) could reliably diagnose specific cardiac conditions such as pericardial effusions, left ventricular dilatation, hypertrophy and failure, and right ventricular dilatation.⁸⁴ One compelling study showed that first-year medical students using hand-carried ultrasound machines had superior diagnostic accuracy when evaluating the ventricular function, valvular disease, and structural abnormalities than did attending cardiologists using only history and physical exam.⁸⁵ Furthermore, anesthesiology residents with only 2 hours of dedicated training were able to use FoCUS to identify severe aortic stenosis.⁸⁶

When it comes to implementing a FoCUS training program, several recent high-yield publications detail the knowledge acquisition and hands-on skill acquisition required to learn and teach a FoCUS exam.^{87 88} Simulation can also provide a dynamic and interactive means to obtain knowledge and acquisition skills with FoCUS.⁷⁶ See table 7 for a description of the education and training goals for FoCUS, structured in the I-AIM framework.

Minimum training recommendations

Two studies have attempted to measure the learning curve for FoCUS exam image acquisition and/or interpretation. As part of a larger study (see "Lung" above for this study's methodology), Blehar *et al* analyzed 5689 FoCUS examinations that had been performed and interpreted by 100 Emergency Medicine-trained ultrasound learners.⁴³ Each exam was scored using a binary scale by experts for the following: (1) image quality (adequate vs inadequate) and (2) learner's interpretation of whether the images showed a pericardial effusion (accurate vs inaccurate). The authors found that the curve plateaued for image acquisition at 27 exams and image interpretation at 30.

Millington *et al* evaluated 380 FoCUS exams performed by 12 physician trainees representing the specialties of anesthesiology (6), critical care (4), emergency medicine (1) and internal

medicine (1).⁸⁹ Two of six intensivists with formal echocardiography training evaluated the FoCUS views (parasternal long axis view, parasternal short axis view, apical 4-chamber view, subcostal 4-chamber view and subcostal-IVC view) and rated image acquisition quality on a five-point scale. Sampling the learners' first 30–50 studies, the authors detected a sustained improvement in image acquisition quality over the first 20 studies, at which point the learning curve began to plateau.

These two studies align with recommendations issued by some professional medical societies. ACEP recommends 25–50 "Level 1" FoCUS exams to achieve competency.⁴⁵ SCCM recommends 30 "Level 1" FoCUS exams and 20 "Level 2" FoCUS exams.⁸ CCCS recommends 30 "Level 1" supervised FoCUS exams.¹³

On reviewing these recommendations, the ASA AHC expressed concern that these training minimums are based on low-quality evidence and may underestimate the optimum training required. For instance, Blehar *et al* evaluated the learning curve only for a single application of FoCUS (screening for pericardial effusion). Similarly, Millington *et al* assessed the learning curve only for image acquisition skills and did not directly measure learners' image interpretation skills. In the opinion of the ASA AHC, mastery of FoCUS requires a greater amount of training than most other POCUS domains. In support of this, Frederiksen *et al* has suggested that competency in FoCUS image acquisition is likely to be achieved after performing 50 supervised training studies.⁸⁴ Further, one institution has reported a high level of anesthesiology resident competency in FoCUS when residents are required to interpret a total of 150 FoCUS exams, of which 50 are personally performed.² Based on these arguments, we recommend the following minimum supervised training numbers for FoCUS-naïve anesthesiologists: 50 "Level 1" FoCUS exams and 100 "Level 2" exams (table 1).⁷

Educational resources

This section highlights the topic of perioperative POCUS education. Relevant to this section is the recent inclusion of POCUS applications in the 2018 Accreditation Council for Graduate Medical Education (ACGME) program requirements for anesthesiology training. This update from the ACGME now reports that anesthesiology residency programs must train on the use of surface ultrasound to evaluate "organ function and pathology as related to anesthesia, critical care, and resuscitation."²⁹ Specific topics listed in the updated program requirements include transthoracic ultrasound for cardiac function/pathology, lung/pulmonary ultrasound and hemodynamic assessment.²⁹ Similarly, the American Board of Anesthesiologists (ABA) has recently expanded its board certification content outline to include the following POCUS topics: focused cardiac, lung, inferior vena cava assessment, bladder and gastric.⁹⁰

For the non-trainee, there are many online resources available for POCUS content education. The American Society of Regional Anesthesiologists has supported a validated online curriculum.⁹¹ This curriculum includes the Basic Focus Assessed Transthoracic Echocardiography protocol developed by an anesthesiologist and is one of the most widely referenced POCUS examination protocols. This content is currently made available to all European Society of Regional Anesthesia members. A recent article series published in regional anesthesia and pain medicine highlights this curriculum.^{87 92–95} Similarly, the Society of Cardiovascular Anesthesiologists (SCA) has an online portal for content training available.⁹⁶ An additional resource is a validated curriculum on the whole-body perioperative ultrasound, termed Focused periOperative Risk Evaluation Sonography

Involving Gastroabdominal Hemodynamic and Transthoracic ultrasound (FORESIGHT), linked to a free-to-access online platform (online supplemental file 2—part II on FORESIGHT curriculum).⁹⁷ Recently, a perioperative POCUS service demonstrated an improvement in the diagnostic accuracy of pathology assessment after completing training via this online curriculum.⁶³ As discussed in the gastric ultrasound section, an expert panel of physicians has developed online educational materials along with case studies that are free to access.⁷⁵ Finally, the anesthesia toolbox,⁹⁸ an online collection of educational materials utilized across many academic anesthesiology programs, has also developed POCUS education modules.

Social media and cloud-based platforms may enhance POCUS education through collaborative learning with mentors or fellow enthusiasts. In particular, Twitter allows access to a wealth of images and facilitates discussion with experts and other learners from all areas of practice by using the hashtag #POCUS. With any of these digital modalities, patient confidentiality must be maintained.

Successful training on perioperative POCUS requires strategies focused on the adult learner.⁴⁰ Education that supports self-directed and/or cooperative learning has been more effective for perioperative POCUS education than traditional pedagogical approaches.⁴⁰

Although these recommendations are from the POCUS expert panel and ASRA leadership, we would still like to highlight that POCUS education courses have become available worldwide with numerous courses using the “flipped classroom” method. We do not endorse any specific courses as many provide excellent opportunities to learn and practice POCUS skills. Many courses target critical care or emergency medicine. Although much of the knowledge and training are transferable between specialties, we recommend courses focusing on the perioperative environment for practicing anesthesiologists and/or pain physicians. At the time of publication, the ASA, International Anesthesia Research Society, ASRA and SCA are all hosting POCUS workshops that differ in their course topics. This current variability further supports this document’s importance in providing anesthesia-specific guidelines for perioperative POCUS competency training. A future goal that also needs to be established is the development of a defined training program(s), which incorporates standardized topics endorsed by all anesthesiology societies. This statement seeks to highlight which topics this expert group believes should be included in such training programs.

Educational barriers to implementation

The successful adoption of a POCUS educational program requires the anticipation of barriers to its creation and developing strategies to mitigate projected obstacles. The most commonly cited perceived barriers to advancing a robust POCUS educational program are lack of adequate equipment, a standardized curriculum, insufficient faculty and time constraints.^{98–103}

Lack of adequate equipment

A recent survey reported that limited access to ultrasound machines was the most significant barrier to incorporating ultrasound into an anesthesiologist’s daily practice.¹⁰⁴ The financial burden of purchasing equipment is also repeatedly cited as a significant barrier to POCUS implementation.^{100 101 105–107} Handheld devices (covered in part I of the recommendations) are a means to overcome the cost barrier of a dedicated POCUS device. Unfortunately, adopting portable technologies may come with institutional resistance when concerns of proprietary cloud

data, electronic medical record integration, or QA reporting fail to meet institutional guidelines and/or policies.

To reduce equipment costs, institution-wide or department-wide standardization of vendors and models can yield distinct advantages, including bulk purchase discounts, upgrades, routine device maintenance and increased clinician familiarity, and simplified integration of technology management activities.^{108 109} Disadvantages include the inability to take advantage of competitor products and/or purchase incentives in between contracted life cycles, as well as institutional inertia when specialty-specific equipment requirements or developments are not shared across all departments.¹⁰⁹

Lack of standardized curriculum

The ABA has recognized the importance of POCUS as evidenced by the inclusion of the subject within the content outlines of the part I examination, the in-training exam, and the APPLIED OSCE, thereby underscoring competency in POCUS as a requisite skill for every anesthesiology residency graduate,^{110–112} However, a single unified curriculum or syllabus is lacking.

Practically speaking, an integrated longitudinal curriculum may be a successful approach for POCUS education, as demonstrated by Ramsingh *et al* (see online supplemental file 2—part II on FORESIGHT curriculum).³ Still, there are multiple educational resources available, as highlighted in the previous section. As part of the curriculum, departmental and institutional QA and quality improvement efforts should align to ensure competent evaluations of image acquisition, interpretation and medical decision-making.

Lack of sufficient faculty

Faculty engagement in POCUS educational efforts is necessary to provide mentoring and oversight of trainee-performed examinations.^{106 107} One approach is the “POCUS champion” model with a skilled faculty member designated as the curriculum leader and provided with dedicated time and financial investment towards curriculum development. The champion will then identify “Core POCUS Faculty” to advance their skillsets and develop POCUS content. Either internal or external CME resources can provide initial training, and ongoing reinforcement of these skills will ensure faculty competency. Interdepartmental and interprofessional collaborations (ie, emergency medicine, radiology, critical care, and/or cardiology) are often necessary to identify additional teaching faculty.¹⁰⁶

Dedicated time for teaching and supervision has consistently been viewed as a significant barrier to POCUS educational efforts.^{100 101 103} Alternatives to traditional teaching modalities include self-directed, self-paced learning using online resources.^{3 113–116} High-fidelity simulators and models remain another option, offering education without the pressure of acute clinical care within the perioperative setting and requiring less faculty supervision. “Near-peer” and “peer-to-peer” methods may potentially reduce the number of faculty required for POCUS skill introduction.^{115–122} Another cost-containing approach is to offer educational workshops for both trainees and faculty contemporaneously, as novice learners may acquire POCUS skills at similar rates regardless of their level of practice.¹²²

Given the tremendous growth potential expected in POCUS adoption, efforts to develop strategies that minimize organizational and educational barriers deserve suitable attention. See [table 8](#) for a summary of these barriers and the means to overcome them. Further research examining how resources can be

Table 8 Summary of barriers to implementation and strategies to overcome barriers

Barrier to implementation	Strategies to overcome barriers
Lack of equipment	Bulk purchasing of equipment Purchase more affordable handheld devices
Lack of standardized curriculum	Employ existing longitudinal curriculum (ie, FORESIGHT) Use other online resources (see education and resources section)
Lack of sufficient qualified faculty	Establish local faculty "Champion" with dedicated time/resources Recruit core faculty to develop competency Use "reverse classroom" and simulator models to optimize faculty time Consider "Near-peer" and "peer-to-peer" models

FORESIGHT, Focused periOperative Risk Evaluation Sonography Involving Gastroabdominal Hemodynamic and Transthoracic ultrasound.

leveraged toward successful POCUS implementation is another opportunity for future growth.

Summary

POCUS is an essential skill for all regional anesthesiologists and pain physicians to help diagnose relevant complications related to routine practice and guide perioperative management. Despite the rapidly growing evidence supporting the utility of POCUS, structured guidelines and strategies for education of the trainee and postgraduate learner, as well as pathways to demonstrate competency, have not been established for the regional anesthesia and pain physician. These recommendations define the core components of POCUS that are relevant for the perioperative setting and provide guidance for training requirements. This document aims to provide regional and pain fellowship training programs with guidance on how to provide adequate training in POCUS to enhance patient safety and management. Additionally, the document can provide direction for postgraduate learners looking to gain competency.

The expert panel acknowledges that obtaining competency is just the first step as maintenance of competency through life-long learning via continued clinical and academic experience is equally important to ensure each clinician stays abreast of the most up-to-date techniques and applications.

Finally, for universal fellowship adaptation, each institution will need to commit to providing training, equipment, and completion of the learning goals for each trainee. In doing so, standardized training and practice will ensure POCUS will be responsibly practiced in the perioperative, acute and chronic pain setting.

Author affiliations

¹Anesthesiology, Critical Care & Pain Management, Hospital for Special Surgery, New York, New York, USA

²Anesthesiology, Weill Cornell Medical College, New York, New York, USA

³Anesthesiology, Duke University School of Medicine, Durham, North Carolina, USA

⁴Anesthesia and Pain Management, Toronto Western Hospital, Toronto, Ontario, Canada

⁵Anaesthesia, Guy's & St Thomas' NHS Foundation Trust, London, UK

⁶Anesthesiology, University of Utah Health, Salt Lake City, Utah, USA

⁷Anesthesiology, Critical Care and Pain Medicine, Harvard Medical School, Boston, Massachusetts, USA

⁸Anesthesiology, McMaster University, Hamilton, Ontario, Canada

⁹Anesthesiology, University of Michigan, Ann Arbor, Michigan, USA

¹⁰Anesthesiology, University of Texas Health Science Center at Houston, Houston, Texas, USA

¹¹Anesthesiology, Stanford Hospital and Clinics, Stanford, California, USA

¹²Anesthesiology, University of Virginia Health System, Charlottesville, Virginia, USA

¹³Anaesthesia, Belfast Health and Social Care Trust, Belfast, UK

¹⁴Intensive Care and Anaesthesia, Northampton General Hospital, Northampton, UK

¹⁵Anesthesiology, UAB, Birmingham, Alabama, USA

¹⁶Anesthesiology, Loma Linda University Medical Center, Loma Linda, California, USA

¹⁷Anesthesiology, Clement Zablocki VA Medical Center/Medical College of Wisconsin, Milwaukee, Wisconsin, USA

¹⁸Anesthesiology, Northwestern University Feinberg School of Medicine, Chicago, Illinois, USA

¹⁹Center for Pain Medicine, Western Reserve Hospital, Cuyahoga Falls, Ohio, USA

Twitter Stephen C Haskins @shaskinsMD, Anahi Perlas @PerlasAnahi, Kariem El-Boghdadly @elboghdadly, Jan Boublik @janboublik MDPhD, Hariharan Shankar @hariharan_shank and Samer Narouze @NarouzeMD

Acknowledgements The authors would like to acknowledge the ASRA Guidelines Committee and the ASRA Board of Directors for their feedback and support in the design of the recommendations. They would also like to thank Professor Erik Sloth, MD, PhD for his ongoing inspiration and permission to present an adaptation of the Focus Assessed Transthoracic Echo Card.

Contributors Only those who made important contributions to the recommendations are included as authors, and all authors are responsible for the content and have read and approved the manuscript for submission to Regional Anesthesia & Pain Medicine.

Funding The authors have not declared a specific grant for this research from any funding agency in the public, commercial or not-for-profit sectors.

Competing interests None declared.

Patient consent for publication Not required.

Provenance and peer review Not commissioned; externally peer reviewed.

Data availability statement There are no data in this work.

ORCID iDs

Stephen C Haskins <http://orcid.org/0000-0001-8012-7594>

Anahi Perlas <http://orcid.org/0000-0002-8190-8314>

Kariem El-Boghdadly <http://orcid.org/0000-0002-9912-717X>

William Clark Manson <http://orcid.org/0000-0002-6308-9036>

Davinder Ramsingh <http://orcid.org/0000-0002-8670-7300>

Samer Narouze <http://orcid.org/0000-0003-1849-1402>

REFERENCES

- Haskins SC, Bronshteyn Y, Perlas A. American Society of Regional Anesthesia and Pain Medicine's expert panel recommendations on point-of-care ultrasound education and training for regional anesthesiologists and pain physicians—part I: clinical indications. *Reg Anesth Pain Med* 2021;1–17.
- Zimmerman J. A recipe for success in echocardiography training: the University of Utah experience. *J Cardiothorac Vasc Anesth* 2018;32:2607–13.
- Ramsingh D, Rinehart J, Kain Z, et al. Impact assessment of perioperative point-of-care ultrasound training on anesthesiology residents. *Anesthesiology* 2015;123:670–82.
- Rashid MM, Lahaye LA, Riley CL. Longitudinal competency-based point-of-care ultrasound curriculum in anesthesiology: description and initial experience with PGY1 and PGY2 trainees. *A & A Practice* 2020;14:155–65.
- National board of echocardiography: application for certification in basic perioperative transesophageal echocardiography. Available: https://www.echoboards.org/docs/BasicPTE_Cert_App-2019.pdf [Accessed 9 Oct 2020].
- Jensen JK, Dyre L, Jørgensen ME, et al. Simulation-Based point-of-care ultrasound training: a matter of competency rather than volume. *Acta Anaesthesiol Scand* 2018;62:811–9.
- American Society of Anesthesiologists (ASA) Ad Hoc Committee on Point-of-Care Ultrasound. Committee work product on diagnostic point-of-care ultrasound, 2019. Available: <https://www.asahq.org/standards-and-guidelines/resources-from-asa-committees#POM> [Accessed Oct 9, 2020].
- Pustavoitau A, Blaiwas M, Brown SM. From the ultrasound certification Task force on behalf of the Society of critical care medicine: recommendations for achieving and

- maintaining competence and credentialing in critical care ultrasound with focused cardiac ultrasound and advanced critical care echocardiography. Society of critical care medicine. Available: <http://journals.lww.com/ccmjournal/Documents/Critical%20Care%20Ultrasound.pdf> [Accessed Oct 9, 2020].
- 9 Meineri M, Bryson GL, Arellano R, et al. Core point-of-care ultrasound curriculum: what does every anesthesiologist need to know? *Can J Anesth/J Can Anesth* 2018;65:417–26.
 - 10 Ma IWY, Arishenkoff S, Wiseman J, et al. Internal medicine point-of-care ultrasound curriculum: consensus recommendations from the Canadian internal medicine ultrasound (CIMUS) group. *J Gen Intern Med* 2017;32:1052–7.
 - 11 Ultrasound guidelines: emergency, point-of-care and clinical ultrasound guidelines in medicine. *Ann Emerg Med* 2017;69:e27–54.
 - 12 Fagley RE, Haney MF, Beraud A-S, et al. Critical care basic ultrasound learning goals for American anesthesiology critical care trainees: recommendations from an expert group. *Anesth Analg* 2015;120:1041–53.
 - 13 Arntfield RT, Millington SJ, Ainsworth CD. Canadian recommendations for critical care ultrasound training and competency for the Canadian critical care Society. *Canadian Respiratory Journal* 2014;21:341–5.
 - 14 Volpicelli G, Elbarbary M, Blaivas M, et al. International liaison Committee on lung ultrasound (ILC-LUS) for international consensus conference on lung ultrasound (ICC-LUS). International evidence based recommendations for point-of-care lung ultrasound. *Intensive Care Med* 2012;38:557–91.
 - 15 McCormick TJ, Miller EC, Chen R, et al. Acquiring and maintaining point-of-care ultrasound (POCUS) competence for anesthesiologists. *Can J Anesth/J Can Anesth* 2018;65:427–36.
 - 16 Frank JR, Snell LS, Cate OT, et al. Competency-Based medical education: theory to practice. *Med Teach* 2010;32:638–45.
 - 17 Miller GE. The assessment of clinical skills/competence/performance. *Academic Medicine* 1990;65:S63–7.
 - 18 Krusselbrink R, Chan V, Cibinel GA, et al. I-AIM (indication, acquisition, interpretation, medical decision-making) framework for point of care lung ultrasound. *Anesthesiology* 2017;127:568–82.
 - 19 Uya A, Spear D, Patel K, et al. Can novice sonographers accurately locate an endotracheal tube with a saline-filled cuff in a cadaver model? A pilot study. *Academic Emergency Medicine* 2012;19:361–4.
 - 20 Tessaro MO, Salant EP, Arroyo AC. Tracheal rapid ultrasound saline test (T.R.U.S.T) for confirming correct endotracheal tube depth in children. *Resuscitation* 2015;89:8–12.
 - 21 Chou HC, Tseng WP, Wang CH. Tracheal rapid ultrasound exam (T.R.U.E.) for confirming endotracheal tube placement during emergency intubation. *Resuscitation* 2011;82:1279–84.
 - 22 Gottlieb M, Bailitz J, Christian E, et al. Accuracy of a novel ultrasound technique for confirmation of endotracheal intubation by expert and novice emergency physicians. *Western Journal of Emergency Medicine* 2014;15:834–9.
 - 23 Chenkin J, McCartney CJL, Jelic T, et al. Defining the learning curve of point-of-care ultrasound for confirming endotracheal tube placement by emergency physicians. *Crit Ultrasound J* 2015;7.
 - 24 Kristensen MS, Teoh WH, Rudolph SS, et al. Structured approach to ultrasound-guided identification of the cricothyroid membrane: a randomized comparison with the palpation method in the morbidly obese. *Br J Anaesth* 2015;114:1003–4.
 - 25 Bahner DP, Hughes D, Royall NA. I-AIM: a novel model for teaching and performing focused sonography. *Journal of Ultrasound in Medicine* 2012;31:295–300.
 - 26 Perlas A, Van de Putte P, Van Houwe P, et al. I-AIM framework for point-of-care gastric ultrasound. *Br J Anaesth* 2016;116:7–11.
 - 27 USabcd. Airway Ultrasonography - USabcd [Internet]. Available: <https://usabcd.org/product/airway-ultrasonography/> [Accessed cited 2020 Oct 09].
 - 28 Hayward M, Chan T, Healey A. Dedicated time for deliberate practice: one emergency medicine program's approach to point-of-care ultrasound (PoCUS) training. *CJEM* 2015;17:558–61.
 - 29 Accreditation Council for Graduate Medical Education/ACGME. *Acgme program requirements for graduate medical education in anesthesiology*, 2018.
 - 30 Emergency ultrasound guidelines. *Ann Emerg Med* 2009;53:550–70.
 - 31 . Available: <https://www.aium.org/resources/guidelines/headNeck.pdf>
 - 32 . Available: <https://www.aium.org/resources/viewStatement.aspx?id=52>
 - 33 . Available: <https://www.aium.org/officialStatements/74>
 - 34 . Available: [https://www.annemergmed.com/article/S0196-0644\(16\)30935-0/pdf](https://www.annemergmed.com/article/S0196-0644(16)30935-0/pdf)
 - 35 Oliveira KF, Arzola C, Ye XY, et al. Determining the amount of training needed for competency of anesthesia trainees in ultrasonographic identification of the cricothyroid membrane. *BMC Anesthesiol* 2017;17:74.
 - 36 You-Ten KE, Siddiqui N, Teoh WH, et al. Point-Of-Care ultrasound (POCUS) of the upper airway. *Can J Anesth/J Can Anesth* 2018;65:473–84.
 - 37 Pietersen PI, Madsen KR, Graumann O, et al. Lung ultrasound training: a systematic review of published literature in clinical lung ultrasound training. *Crit Ultrasound J* 2018;10.
 - 38 Soon AW, Toney AG, Stidham T. Teaching point-of-care lung ultrasound to novice pediatric learners: web-based e-learning versus traditional classroom Didactic. *Pediatric emergency care* 2020;36:317–21.
 - 39 Edrich T, Stopfkuchen-Evans M, Scheiermann P, et al. A comparison of web-based with traditional classroom-based training of lung ultrasound for the exclusion of pneumothorax. *Anesthesia & Analgesia* 2016;123:123–8.
 - 40 Ramsingh D, Alexander B, Le K, et al. Comparison of the didactic lecture with the simulation/model approach for the teaching of a novel perioperative ultrasound curriculum to anesthesiology residents. *J Clin Anesth* 2014;26:443–54.
 - 41 Cartier RA, Skinner C, Laselle B. Perceived Effectiveness of Teaching Methods for Point of Care Ultrasound. *J Emerg Med* 2014;47:86–91.
 - 42 Goffi A, Krusselbrink R, Volpicelli G. The sound of air: point-of-care lung ultrasound in perioperative medicine. *Can J Anesth/J Can Anesth* 2018;65:399–416.
 - 43 Blehar DJ, Barton B, Gaspari RJ. Learning curves in emergency ultrasound education. *Academic Emergency Medicine* 2015;22:574–82.
 - 44 Arbelot C, Neto FLD, Gao Y. Lung ultrasound in emergency and critically ill patients: number of supervised exams to reach basic competence. *Anesthesiology* 2020;132:899–907.
 - 45 American College of Emergency Physicians (ACEP). Ultrasound guidelines: emergency point-of-care and clinical ultrasound guidelines in medicine, 2016. Available: <https://www.acep.org/globalassets/new-pdfs/policy-statements/ultrasound-guidelines-emergency-point-of-care-and-clinical-ultrasound-guidelines-in-medicine.pdf> [Accessed Oct 9, 2020].
 - 46 Wong A, Galarza L, Duska F. Critical care ultrasound: a systematic review of international training competencies and program. *Critical Care Medicine* 2019;47:e256–62.
 - 47 Ford JW, Heiberg J, Brennan AP, et al. A pilot assessment of 3 point-of-care strategies for diagnosis of perioperative lung pathology. *Anesthesia & Analgesia* 2017;124:734–42.
 - 48 Bouhemad B, Zhang M, Lu Q, et al. Clinical review: bedside lung ultrasound in critical care practice. *Critical Care* 2007;11:205.
 - 49 Rebel A, Srour H, DiLorenzo A, et al. Ultrasound skill and application of knowledge assessment using an innovative OSCE Competition-Based simulation approach. *J Educ Perioper Med* 2016;18:E404.
 - 50 Gracias VH, Frankel HL, Gupta R, et al. Defining the learning curve for the focused abdominal Sonogram for trauma (fast) examination: implications for credentialing. *Am Surg* 2001;67:364–8.
 - 51 Shokoohi H, Boniface K, Kaviany P, et al. An experiential learning model facilitates learning of bedside ultrasound by preclinical medical students. *J Surg Educ* 2016;73:208–14.
 - 52 Brandli L. Benefits of protocol-driven ultrasound exams. *Radiol Manage* 2007;29:56–9 <https://europepmc.org/article/med/17696073>
 - 53 Perlas A, Arzola C, Van de Putte P. Point-Of-Care gastric ultrasound and aspiration risk assessment: a narrative review. *Can J Anesth/J Can Anesth* 2018;65:437–48.
 - 54 Cubillos J, Tse C, Chan VWS, et al. Bedside ultrasound assessment of gastric content: an observational study. *Can J Anesth/J Can Anesth* 2012;59:416–23.
 - 55 Perlas A, Mitsakakis N, Liu L, et al. Validation of a mathematical model for ultrasound assessment of gastric volume by gastroscopic examination. *Anesthesia & Analgesia* 2013;116:357–63.
 - 56 Krusselbrink R, Arzola C, Jackson T, et al. Ultrasound assessment of gastric volume in severely obese individuals: a validation study. *Br J Anaesth* 2017;118:77–82.
 - 57 Krusselbrink R, Gharapetian A, Chaparro LE, et al. Diagnostic accuracy of point-of-care gastric ultrasound. *Anesth Analg* 2019;128:89–95.
 - 58 Hasan A, Alrayashi W, Waisel D, et al. A case report of incidental hepatic cysts found on ultrasound imaging. *A & A Practice* 2018;10:33–5.
 - 59 Van de Putte P, Perlas A. Ultrasound assessment of gastric content and volume. *Br J Anaesth* 2014;113:12–22.
 - 60 Haskins SC, Feldman D, Fields KG, et al. Teaching a point-of-care ultrasound curriculum to anesthesiology trainees with traditional Didactic lectures or an online e-learning platform: a pilot study. *J Educ Perioper Med* 2018;20:1.
 - 61 Ruiz JG, Mintzer MJ, Leipzig RM. The impact of e-learning in medical education. *Academic Medicine* 2006;81:207–12.
 - 62 Cook DA, Levinson AJ, Garside S. Time and learning efficiency in Internet-based learning: a systematic review and meta-analysis. *Advances in Health Sciences Education* 2010;15:755–70.
 - 63 Ramsingh D, Runyon A, Gatling J, et al. Improved diagnostic accuracy of pathology with the implementation of a perioperative point-of-care ultrasound service: quality improvement initiative. *Reg Anesth Pain Med* 2020;45:95–101.
 - 64 Rajamani A, Miu M, Huang S, et al. Impact of critical care point-of-care ultrasound short-courses on trainee competence. *Crit Care Med* 2019;47:e782–4.
 - 65 Kimura BJ, Sliman SM, Waalen J, et al. Retention of Ultrasound Skills and Training in "Point-of-Care" Cardiac Ultrasound. *J Am Soc Echocardiogr* 2016;29:992–7.
 - 66 Arzola C, Carvalho JCA, Cubillos J, et al. Anesthesiologists' learning curves for bedside qualitative ultrasound assessment of gastric content: a cohort study. *Can J Anesth/J Can Anesth* 2013;60:771–9.
 - 67 Perlas A, Chan VWS, Lupu CM, et al. Ultrasound assessment of gastric content and volume. *Anesthesiology* 2009;111:82–9.
 - 68 Smith CJ, Matthias T, Beam E, et al. Building a bigger tent in point-of-care ultrasound education: a mixed-methods evaluation of interprofessional, near-peer teaching of internal medicine residents by sonography students. *BMC Med Educ* 2018;18:321.

- 69 Cormack CJ, Coombs PR, Guskich KE, *et al*. Collaborative model for training and credentialing point-of-care ultrasound: 6-year experience and quality outcomes. *J Med Imaging Radiat Oncol* 2018;62:330–6.
- 70 Jang TB, Jack Casey R, Dyne P, *et al*. The learning curve of resident physicians using emergency ultrasonography for obstructive uropathy. *Academic Emergency Medicine* 2010;17:1024–7.
- 71 Nair P, Siu SC, Sloggett CE, *et al*. The assessment of technical and interpretative proficiency in echocardiography. *Journal of the American Society of Echocardiography* 2006;19:924–31.
- 72 Duanmu Y, Henwood PC, Takhar SS, *et al*. Correlation of OSCE performance and point-of-care ultrasound scan numbers among a cohort of emergency medicine residents. *The Ultrasound Journal* 2019;11:3.
- 73 Lucas BP, Tierney DM, Jensen TP, *et al*. Credentialing of hospitalists in ultrasound-guided bedside procedures: a position statement of the Society of hospital medicine. *Journal of Hospital Medicine* 2018;13:117–25.
- 74 Lewis RE, Pearl M, Nomura JT, *et al*. CORD-AEUS: consensus document for the emergency ultrasound milestone project. *Academic Emergency Medicine* 2013;20:740–5.
- 75 . Available: www.gastricultrasound.org [Accessed October 2020].
- 76 Neelankavil J, Howard-Quijano K, Hsieh TC, *et al*. Transthoracic echocardiography simulation is an efficient method to train anesthesiologists in basic transthoracic echocardiography skills. *Anesth Analg* 2012;115:1042–51.
- 77 Adhikary SD, Hadzic A, McQuillan PM. Simulator for teaching hand–eye coordination during ultrasound-guided regional anaesthesia. *Br J Anaesth* 2013;111:844–5.
- 78 Woodworth GE, Chen EM, Horn J-LE, *et al*. Efficacy of computer-based video and simulation in ultrasound-guided regional anesthesia training. *J Clin Anesth* 2014;26:212–21.
- 79 Todsén T, Tolsgaard MG, Olsen BH, *et al*. Reliable and valid assessment of point-of-care ultrasonography. *Ann Surg* 2015;261:309–15.
- 80 Skaarup SH, Laursen CB, Bjerrum AS, *et al*. Objective and structured assessment of lung ultrasound competence. A Multispecialty Delphi consensus and construct validity study. *Ann Am Thorac Soc* 2017;14:555–60.
- 81 Zimmerman JM, Coker BJ. The nuts and bolts of performing focused cardiovascular ultrasound (focus). *Anesthesia & Analgesia* 2017;124:753–60.
- 82 Spencer KT, Kimura BJ, Korcarz CE, *et al*. Focused cardiac ultrasound: recommendations from the American Society of echocardiography. *Journal of the American Society of Echocardiography* 2013;26:567–81.
- 83 Via G, Hussain A, Wells M, *et al*. International evidence-based recommendations for focused cardiac ultrasound. *Journal of the American Society of Echocardiography* 2014;27:683.e1–683.e33.
- 84 Frederiksen CA, Juhl-Olsen P, Andersen NH, *et al*. Assessment of cardiac pathology by point-of-care ultrasonography performed by a novice examiner is comparable to the gold standard. *Scand J Trauma Resusc Emerg Med* 2013;21:87.
- 85 Kobal SL, Trento L, Baharami S, *et al*. Comparison of effectiveness of hand-carried ultrasound to bedside cardiovascular physical examination. *Am J Cardiol* 2005;96:1002–6.
- 86 Cowie B, Kluger R. Evaluation of systolic murmurs using transthoracic echocardiography by anaesthetic trainees. *Anaesthesia* 2011;66:785–90.
- 87 Haskins SC, Tanaka CY, Boublik J, *et al*. Focused cardiac ultrasound for the regional anesthesiologist and pain specialist. *Reg Anesth Pain Med* 2017;42:632–44.
- 88 Coker BJ, Zimmerman JM. Why Anesthesiologists must incorporate focused cardiac ultrasound into daily practice. *Anesthesia & Analgesia* 2017;124:761–5.
- 89 Millington SJ, Hewak M, Arntfield RT, *et al*. Outcomes from extensive training in critical care echocardiography: identifying the optimal number of practice studies required to achieve competency. *J Crit Care* 2017;40:99–102.
- 90 "Primary Certification in Anesthesiology." Available: <http://www.theaba.org/PDFs/BASIC-Exam/Basic-and-Advanced-ContentOutline> [Accessed 18 Nov 2018].
- 91 . Available: USabcd.org
- 92 Haskins SC, Boublik J, Wu CL. Point-Of-Care ultrasound for the regional anesthesiologist and pain specialist: a series introduction. *Reg Anesth Pain Med* 2017;42:281–2.
- 93 Haskins SC, Krusselbrink R, Boublik J, *et al*. Gastric ultrasound for the regional anesthesiologist and pain specialist. *Reg Anesth Pain Med* 2018;42:1.
- 94 Haskins SC, Tsui BC, Nejim JA, *et al*. Lung ultrasound for the regional anesthesiologist and acute pain specialist. *Reg Anesth Pain Med* 2017;42:289–98.
- 95 Manson WC, Kirksey M, Boublik J, *et al*. Focused assessment with sonography in trauma (fast) for the regional anesthesiologist and pain specialist. *Reg Anesth Pain Med* 2019;44:540–8.
- 96 . Available: <http://www.iteachu.com>
- 97 . Available: www.foresightultrasound.com
- 98 Pulton D, Feinman J. Hocus POCUS: making barriers to perioperative point-of-care ultrasound disappear. *J Cardiothorac Vasc Anesth* 2019;33:2419–20.
- 99 Flick D. Bedside ultrasound education in primary care. *J Ultrasound Med* 2016;35:1369–71.
- 100 Eisen LA, Leung S, Gallagher AE, *et al*. Barriers to ultrasound training in critical care medicine fellowships: a survey of program directors. *Crit Care Med* 2010;38:1978–83.
- 101 Dinh VA, Fu JY, Lu S, *et al*. Integration of ultrasound in medical education at United States medical schools: a national survey of directors' experiences. *J Ultrasound Med* 2016;35:413–9.
- 102 Schnobrich DJ, Gladding S, Olson APJ, *et al*. Point-Of-Care ultrasound in internal medicine: a national survey of educational leadership. *J Grad Med Educ* 2013;5:498–502.
- 103 Leschyna M, Hatam E, Britton S, *et al*. Current state of point-of-care ultrasound usage in Canadian emergency departments. *Cureus* 2019;11.
- 104 Chui J, Lavi R, Hegazy AF, *et al*. Identifying barriers to the use of ultrasound in the perioperative period: a survey of southwestern Ontario anesthesiologists. *BMC Health Serv Res* 2019;19.
- 105 Beal EW, Sigmond BR, Sage-Silski L, *et al*. Point-Of-Care ultrasound in general surgery residency training: a proposal for milestones in graduate medical education ultrasound. *J Ultrasound Med* 2017;36:2577–84.
- 106 LoPresti CM, Schnobrich DJ, Dversdal RK, *et al*. A road map for point-of-care ultrasound training in internal medicine residency. *Ultrasound J* 2019;11:10.
- 107 Heller MB, Mandavia D, Tayal VS, *et al*. Residency training in emergency ultrasound: fulfilling the mandate. *Acad Emerg Med* 2002;9:835–9.
- 108 ECRI Institute. Adoption of point-of-care ultrasound is outpacing safeguards. Available: <https://www.ecri.org/landing-2020-top-ten-health-technology-hazards> [Accessed 9 Oct 2020].
- 109 Strony R, Marin J, Baillit J, *et al*. Systemwide clinical ultrasound program development: an expert consensus model. *West J Emerg Med* 2018;19:649–53.
- 110 . Available: <https://theaba.org/PDFs/Traditional-Part-1-Exam/Part1ContentOutline> [Accessed 9 Oct 2020].
- 111 . Available: <https://theaba.org/PDFs/ITE-Exam/ITEContentOutline> [Accessed 9 Oct 2020].
- 112 . Available: <https://theaba.org/PDFs/APPLIED-Exam/APPLIED-OSCE-ContentOutline> [Accessed 9 Oct 2020].
- 113 Tolsgaard MG, Ringsted C, Dreisler E, *et al*. Sustained effect of simulation-based ultrasound training on clinical performance: a randomized trial. *Ultrasound Obstet Gynecol* 2015;46:312–8.
- 114 Hempel D, Stenger T, Campo dell'Orto M, *et al*. Analysis of trainees' memory after classroom presentations of didactical ultrasound courses. *Crit Ultrasound J* 2014;6:10.
- 115 McGaghie WC, Issenberg SB, Barsuk JH, *et al*. A critical review of simulation-based mastery learning with translational outcomes. *Med Educ* 2014;48:375–85.
- 116 Sekiguchi H, Bhagra A, Gajic O, *et al*. A general critical care ultrasonography workshop: results of a novel web-based learning program combined with simulation-based hands-on training. *J Crit Care* 2013;28:217.e7.
- 117 Jeppesen KM, Bahner DP. Teaching bedside sonography using peer mentoring: a prospective randomized trial. *J Ultrasound Med* 2012;31:455–9.
- 118 Knobe M, Münker R, Sellei RM, *et al*. Peer teaching: a randomised controlled trial using student-teachers to teach musculoskeletal ultrasound. *Med Educ* 2010;44:148–55.
- 119 Naeger DM, Conrad M, Nguyen J. Students teaching students: Evaluation of a "near-peer" teaching experience. *Academic Radiology* 2013;20:1177–82.
- 120 Yamada T, Minami T, Soni NJ, *et al*. Skills acquisition for novice learners after a point-of-care ultrasound course: does clinical RANK matter? *BMC Med Educ* 2018;18:202.
- 121 Ahn JS, French AJ, Thiessen MEW, *et al*. Training peer instructors for a combined ultrasound/physical exam curriculum. *Teach Learn Med* 2014;26:292–5.
- 122 Garcia-Casasola G, Sánchez FJG, Luordo D, *et al*. Basic abdominal point-of-care ultrasound training in the undergraduate: students as mentors. *J Ultrasound Med* 2016;35:2483–9.

Supplement 1 – I-AIM Checklists for POCUS Skills

Airway POCUS Education & Training Goals Checklist				
Indications				
<i>Does the learner understand the following indications?</i>	Yes	No	Uncertain	Comments
To aid in location of the cricothyroid membrane	<input type="checkbox"/>	<input type="checkbox"/>	<input type="checkbox"/>	
To aid in location of the cricoid cartilage	<input type="checkbox"/>	<input type="checkbox"/>	<input type="checkbox"/>	
To aid in location of tracheal rings	<input type="checkbox"/>	<input type="checkbox"/>	<input type="checkbox"/>	
To confirm of oro- or nasogastric tube placement	<input type="checkbox"/>	<input type="checkbox"/>	<input type="checkbox"/>	
To confirm correct endotracheal tube placement	<input type="checkbox"/>	<input type="checkbox"/>	<input type="checkbox"/>	
Image acquisition				
<i>Has the learner imaged the following structures in sagittal and transverse planes?</i>	Yes	No	Uncertain	Comments
Thyroid cartilage	<input type="checkbox"/>	<input type="checkbox"/>	<input type="checkbox"/>	
Vocal Cords	<input type="checkbox"/>	<input type="checkbox"/>	<input type="checkbox"/>	
Cricothyroid membrane	<input type="checkbox"/>	<input type="checkbox"/>	<input type="checkbox"/>	
Cricoid cartilage	<input type="checkbox"/>	<input type="checkbox"/>	<input type="checkbox"/>	
Hyoid	<input type="checkbox"/>	<input type="checkbox"/>	<input type="checkbox"/>	
Tracheal rings	<input type="checkbox"/>	<input type="checkbox"/>	<input type="checkbox"/>	
Esophagus	<input type="checkbox"/>	<input type="checkbox"/>	<input type="checkbox"/>	
Thyroid gland	<input type="checkbox"/>	<input type="checkbox"/>	<input type="checkbox"/>	
Surrounding vasculature (carotid artery, jugular veins etc)	<input type="checkbox"/>	<input type="checkbox"/>	<input type="checkbox"/>	
Image interpretation				
<i>Can the learner successfully interpret the following imaging?</i>	Yes	No	Uncertain	Comments
Cricothyroid membrane	<input type="checkbox"/>	<input type="checkbox"/>	<input type="checkbox"/>	
Cricoid cartilage	<input type="checkbox"/>	<input type="checkbox"/>	<input type="checkbox"/>	
Tracheal rings	<input type="checkbox"/>	<input type="checkbox"/>	<input type="checkbox"/>	

Confirmation of the esophageal location of oro- or nasogastric tube	<input type="checkbox"/>	<input type="checkbox"/>	<input type="checkbox"/>	
Confirmation of intra-tracheal and excluding esophageal tracheal tube placement	<input type="checkbox"/>	<input type="checkbox"/>	<input type="checkbox"/>	
Medical decision-making				
<i>Does the learner understand the appropriate medical-decision-making?</i>	Yes	No	Uncertain	Comments
Image the cricothyroid membrane in longitudinal and transverse planes and mark the skin for the correct location of emergent cricothyrotomy	<input type="checkbox"/>	<input type="checkbox"/>	<input type="checkbox"/>	
Determine and mark the skin for the correct location of cricoid force (pressure)	<input type="checkbox"/>	<input type="checkbox"/>	<input type="checkbox"/>	
Determine the safe utilization of an oro- or nasogastric tube for gastric decompression or feeding	<input type="checkbox"/>	<input type="checkbox"/>	<input type="checkbox"/>	

Lung Ultrasound Education & Training Goals Checklist				
Indications				
<i>Does the learner understand the following indications?</i>	Yes	No	Uncertain	Comments
Pneumothorax	<input type="checkbox"/>	<input type="checkbox"/>	<input type="checkbox"/>	
Effusions / Blood	<input type="checkbox"/>	<input type="checkbox"/>	<input type="checkbox"/>	
Diaphragmatic paresis	<input type="checkbox"/>	<input type="checkbox"/>	<input type="checkbox"/>	
Interstitial Syndrome	<input type="checkbox"/>	<input type="checkbox"/>	<input type="checkbox"/>	
<i>Does the learner understand the following limitations or pitfalls?</i>	Yes	No	Uncertain	Comments
Previous thoracic surgery (pneumonectomy, pleurodesis)	<input type="checkbox"/>	<input type="checkbox"/>	<input type="checkbox"/>	
Severe pre-existing lung disease (Bullae, pulmonary fibrosis, septations, emphysema), lung contusion/consolidation	<input type="checkbox"/>	<input type="checkbox"/>	<input type="checkbox"/>	
Small effusions, intraperitoneal fluid, loculated/complex collections	<input type="checkbox"/>	<input type="checkbox"/>	<input type="checkbox"/>	
Mechanical ventilation, apnea, Ascites, subphrenic fluid accumulation	<input type="checkbox"/>	<input type="checkbox"/>	<input type="checkbox"/>	
Image acquisition				
<i>Has the learner imaged the following structures for pneumothorax?</i>	Yes	No	Uncertain	Comments
Superior and inferior ribs and their shadows (Batwing sign)	<input type="checkbox"/>	<input type="checkbox"/>	<input type="checkbox"/>	
Pleural line	<input type="checkbox"/>	<input type="checkbox"/>	<input type="checkbox"/>	
<i>Has the learner imaged the following structures for effusion/blood?</i>	Yes	No	Uncertain	Comments
Diaphragm	<input type="checkbox"/>	<input type="checkbox"/>	<input type="checkbox"/>	
Anterior chest wall	<input type="checkbox"/>	<input type="checkbox"/>	<input type="checkbox"/>	
Lung parenchyma	<input type="checkbox"/>	<input type="checkbox"/>	<input type="checkbox"/>	
<i>Has the learner imaged the following structures for diaphragmatic movement?</i>	Yes	No	Uncertain	Comments
The mid-axillary line at the 8th – 9 th Intercostal space	<input type="checkbox"/>	<input type="checkbox"/>	<input type="checkbox"/>	
Midclavicular/anterior axillary line at the subcostal region	<input type="checkbox"/>	<input type="checkbox"/>	<input type="checkbox"/>	
Image interpretation				

<i>Can the learner successfully interpret the following imaging to rule out a pneumothorax?</i>	Yes	No	Uncertain	Comments
Lung sliding/pulse	<input type="checkbox"/>	<input type="checkbox"/>	<input type="checkbox"/>	
Vertical artifacts (B-lines, comet tail)	<input type="checkbox"/>	<input type="checkbox"/>	<input type="checkbox"/>	
Seashore sign	<input type="checkbox"/>	<input type="checkbox"/>	<input type="checkbox"/>	
<i>Can the learner successfully interpret the following imaging to diagnose a pneumothorax?</i>	Yes	No	Uncertain	Comments
Lung point	<input type="checkbox"/>	<input type="checkbox"/>	<input type="checkbox"/>	
Absence of lung sliding and A-line pattern	<input type="checkbox"/>	<input type="checkbox"/>	<input type="checkbox"/>	
Barcode sign	<input type="checkbox"/>	<input type="checkbox"/>	<input type="checkbox"/>	
<i>Can the learner successfully interpret the following imaging to assess for an effusion/blood?</i>	Yes	No	Uncertain	Comments
Curtain Sign (rule out effusion)	<input type="checkbox"/>	<input type="checkbox"/>	<input type="checkbox"/>	
Anechoic collection cephalad to the diaphragm	<input type="checkbox"/>	<input type="checkbox"/>	<input type="checkbox"/>	
Spine sign	<input type="checkbox"/>	<input type="checkbox"/>	<input type="checkbox"/>	
Sinusoid sign	<input type="checkbox"/>	<input type="checkbox"/>	<input type="checkbox"/>	
<i>Can the learner successfully interpret the following imaging to assess for diaphragmatic function?</i>	Yes	No	Uncertain	Comments
Δ tdi (Change in diaphragm thickness between end-expiration and end-inspiration) < 20%	<input type="checkbox"/>	<input type="checkbox"/>	<input type="checkbox"/>	
Excursion less than 1.8cm during quiet breathing or less than 4.8cm during deep breathing	<input type="checkbox"/>	<input type="checkbox"/>	<input type="checkbox"/>	
Paradoxical movement on inspiration (towards probe)	<input type="checkbox"/>	<input type="checkbox"/>	<input type="checkbox"/>	
Medical decision-making				
<i>Does the learner understand the appropriate medical decision-making for pneumothorax?</i>	Yes	No	Uncertain	Comments
Observe vs. needle decompression vs. chest tube vs. pigtail	<input type="checkbox"/>	<input type="checkbox"/>	<input type="checkbox"/>	

<i>Does the learner understand the appropriate medical decision-making for effusion or blood?</i>	Yes	No	Uncertain	Comments
Observation vs. chest-tube vs. thoracotomy	<input type="checkbox"/>	<input type="checkbox"/>	<input type="checkbox"/>	
<i>Does the learner understand the appropriate medical decision-making for diaphragmatic dysfunction?</i>	Yes	No	Uncertain	Comments
Supportive measurements	<input type="checkbox"/>	<input type="checkbox"/>	<input type="checkbox"/>	
NIMV vs. intubation	<input type="checkbox"/>	<input type="checkbox"/>	<input type="checkbox"/>	

Gastric Ultrasound Education & Training Goals Checklist				
Indications				
<i>Does the learner understand the following indications and limitations?</i>	Yes	No	Uncertain	Comments
Unclear history and/or unknown fasting status	<input type="checkbox"/>	<input type="checkbox"/>	<input type="checkbox"/>	
Urgent surgery	<input type="checkbox"/>	<input type="checkbox"/>	<input type="checkbox"/>	
Risk factors for delayed gastric emptying	<input type="checkbox"/>	<input type="checkbox"/>	<input type="checkbox"/>	
Limitation: Previous gastric surgery	<input type="checkbox"/>	<input type="checkbox"/>	<input type="checkbox"/>	
Limitation: Large hiatal hernia	<input type="checkbox"/>	<input type="checkbox"/>	<input type="checkbox"/>	
Image acquisition				
<i>Has the learner imaged the following structures in the supine and right lateral decubitus position?</i>	Yes	No	Uncertain	Comments
Liver	<input type="checkbox"/>	<input type="checkbox"/>	<input type="checkbox"/>	
Gastric Antrum	<input type="checkbox"/>	<input type="checkbox"/>	<input type="checkbox"/>	
Pancreas	<input type="checkbox"/>	<input type="checkbox"/>	<input type="checkbox"/>	
Abdominal Aorta	<input type="checkbox"/>	<input type="checkbox"/>	<input type="checkbox"/>	
Thoracic Spine	<input type="checkbox"/>	<input type="checkbox"/>	<input type="checkbox"/>	
Image interpretation				
<i>Can the learner successfully interpret the following qualitative findings?</i>	Yes	No	Uncertain	Comments
Empty (no content)	<input type="checkbox"/>	<input type="checkbox"/>	<input type="checkbox"/>	
Clear Fluid	<input type="checkbox"/>	<input type="checkbox"/>	<input type="checkbox"/>	
Solid (early)	<input type="checkbox"/>	<input type="checkbox"/>	<input type="checkbox"/>	
Solid (late)	<input type="checkbox"/>	<input type="checkbox"/>	<input type="checkbox"/>	
Thick fluid	<input type="checkbox"/>	<input type="checkbox"/>	<input type="checkbox"/>	
<i>Can the learner successfully interpret the following quantitative findings?</i>	Yes	No	Uncertain	Comments
Estimate volume based on a cross sectional area (CSA) of the antrum in the RLD	<input type="checkbox"/>	<input type="checkbox"/>	<input type="checkbox"/>	
Medical decision-making				
<i>Does the learner understand the appropriate medical decision-making for gastric ultrasound with an empty stomach</i>	Yes	No	Uncertain	Comments

<i>(no content or low fluid volume (<1.5 mL/Kg)?</i>				
Proceed with the case with no special aspiration precautions indicated	<input type="checkbox"/>	<input type="checkbox"/>	<input type="checkbox"/>	
<i>Does the learner understand the appropriate medical decision-making for gastric ultrasound with solid content or high fluid volume (>1.5 mL/Kg)?</i>	Yes	No	Uncertain	Comments
Consider postponing if elective with recent intake	<input type="checkbox"/>	<input type="checkbox"/>	<input type="checkbox"/>	
If need to proceed, then use aspiration prophylaxis (e.g. awake patient or tracheal intubation, rapid sequence induction)	<input type="checkbox"/>	<input type="checkbox"/>	<input type="checkbox"/>	
<i>Does the learner understand the appropriate medical decision-making for gastric ultrasound with unclear/equivocal imaging?</i>	Yes	No	Uncertain	Comments
Manage based on available clinical information and local policies regarding fasting guidelines	<input type="checkbox"/>	<input type="checkbox"/>	<input type="checkbox"/>	

Focused Cardiac Ultrasound Education & Training Goals Checklist				
Indications				
<i>Does the learner understand the following indications and limitations?</i>	Yes	No	Uncertain	Comments
Hemodynamic instability or undifferentiated shock	<input type="checkbox"/>	<input type="checkbox"/>	<input type="checkbox"/>	
Cardiac arrest	<input type="checkbox"/>	<input type="checkbox"/>	<input type="checkbox"/>	
Pericardial effusion/tamponade: signs and symptoms	<input type="checkbox"/>	<input type="checkbox"/>	<input type="checkbox"/>	
Heart failure: signs and symptoms	<input type="checkbox"/>	<input type="checkbox"/>	<input type="checkbox"/>	
High cardiac risk patients	<input type="checkbox"/>	<input type="checkbox"/>	<input type="checkbox"/>	
Adjunct to physical examination	<input type="checkbox"/>	<input type="checkbox"/>	<input type="checkbox"/>	
Image acquisition				
<i>Has the learner imaged the following structures?</i>	Yes	No	Uncertain	Comments
Parasternal Long Axis (PLAX)	<input type="checkbox"/>	<input type="checkbox"/>	<input type="checkbox"/>	
Parasternal Short Axis (PSAX)	<input type="checkbox"/>	<input type="checkbox"/>	<input type="checkbox"/>	
Apical 4-Chamber View (A4CH)	<input type="checkbox"/>	<input type="checkbox"/>	<input type="checkbox"/>	
Subcostal 4 Chamber (SC4CH)	<input type="checkbox"/>	<input type="checkbox"/>	<input type="checkbox"/>	
Subcostal Inferior Vena Cava (SCIVC)	<input type="checkbox"/>	<input type="checkbox"/>	<input type="checkbox"/>	
Image interpretation				
<i>Can the learner successfully interpret the following qualitative findings?</i>	Yes	No	Uncertain	Comments
Ventricular dimensions and systolic function	<input type="checkbox"/>	<input type="checkbox"/>	<input type="checkbox"/>	
Volume status/responsiveness	<input type="checkbox"/>	<input type="checkbox"/>	<input type="checkbox"/>	
Pericardial effusion/tamponade	<input type="checkbox"/>	<input type="checkbox"/>	<input type="checkbox"/>	
Gross anatomical abnormalities	<input type="checkbox"/>	<input type="checkbox"/>	<input type="checkbox"/>	
Gross signs of chronic heart disease	<input type="checkbox"/>	<input type="checkbox"/>	<input type="checkbox"/>	
Medical decision-making				
<i>Does the learner understand the appropriate medical decision-making for the following pathology?</i>	Yes	No	Uncertain	Comments
Local anesthetic systemic toxicity (LAST)	<input type="checkbox"/>	<input type="checkbox"/>	<input type="checkbox"/>	
Aortic stenosis (AS)	<input type="checkbox"/>	<input type="checkbox"/>	<input type="checkbox"/>	
Hypovolemia	<input type="checkbox"/>	<input type="checkbox"/>	<input type="checkbox"/>	

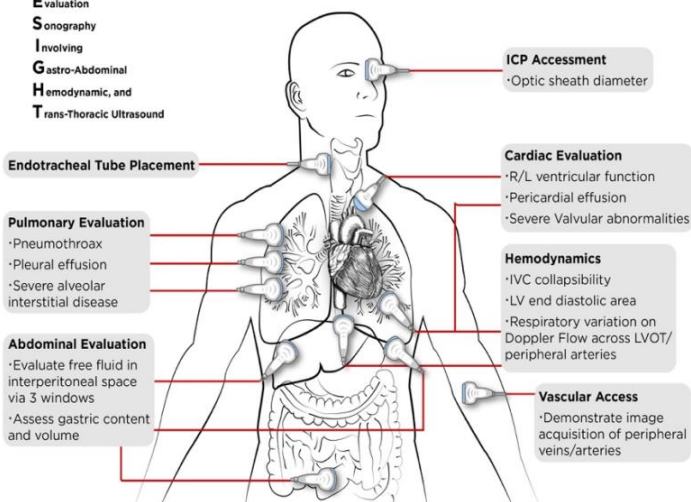
Massive pulmonary embolism	<input type="checkbox"/>	<input type="checkbox"/>	<input type="checkbox"/>	
Pericardial effusion/tamponade	<input type="checkbox"/>	<input type="checkbox"/>	<input type="checkbox"/>	
Gross ventricular failure	<input type="checkbox"/>	<input type="checkbox"/>	<input type="checkbox"/>	

Acute Care and Perioperative Point of Care Ultrasound

Helping Bring Providers Out of the Guessing Game

F.O.R.E.S.I.G.H.T. Comprehensive Perioperative Ultrasound Examination

Focused
Peri**O**perative
Risk
Evaluation
Sonography
Involving
Gastro-Abdominal
Hemodynamic, and
Trans-Thoracic Ultrasound



- I.** **Ultrasound Physics**
- II.** **Assessment of Volume Status/Mechanism of Hypotension**
 - A.** IVC Diameter and Collapsibility
 - B.** Left Ventricle End-Diastolic Area
 - C.** Respiratory Variation of Velocity Time Integral
 - D.** FAST (Focused Assessment with Sonography for Trauma) Exam
- III.** **Pulmonary Ultrasound**
 - A.** Pneumothorax Evaluation
 - B.** Pleural Fluid Evaluation
 - C.** Lung Parenchyma Evaluation
- IV.** **Cardiac Ultrasound**
 - A.** Parasternal Views and Assessment of Left Ventricular Contractility
 - B.** Apical Views
 - C.** Subxiphoid Views.
 - D.** Tips for Cardiac Ultrasound Imaging
 - E.** Cardiac Valve Evaluation
 - F.** Cardiac Ultrasound for Patients with Diastolic and Systolic Heart Failure
 - G.** Right Ventricular Systolic Function Assessment
- V.** **Additional Topics**
 - A.** Vascular Access
 - B.** Deep Venous Thrombosis Evaluation
 - C.** Pulmonary Embolus Evaluation
 - D.** Gastric Volume Assessment
 - E.** Intracranial Pressure Assessment
 - F.** Airway Ultrasound and Localization of Endotracheal Tube.
- VI.** **FORESIGHT Exam Review Sheets, Questions and Answers**