

#35921 ULTRASOUND GUIDED REGIONAL ANAESTHESIA IN RURAL INDIA: A BOON FOR TIDING OVER HIGH RISK TRAUMA CASES

¹Aarushi Jain*, ²Balavenkatasubramanian Jagannathan. ¹Department of Anaesthesia, Vardhman Trauma and Laparoscopy Centre, Muzaffarnagar, India; ²Department of Anaesthesia, Ganga Medical Centre and Hospital Pvt Limited, Coimbatore, India

10.1136/rapm-2023-ESRA.660

Please confirm that an ethics committee approval has been applied for or granted: Not relevant (see information at the bottom of this page)

Application for ESRA Abstract Prizes: I apply as an Anaesthesiologist (Aged 35 years old or less)

Background and Aims The use of ultrasound for precise delivery of local anaesthetics has been a breakthrough in the field of regional anaesthesia. However, it has still not found its place in many small towns of the developing nations. Lack of trained anaesthesiologists, inaccessibility to the required armamentarium and resistance from surgeons are prime factors responsible for the same. Our aim was to establish ultrasound guided regional anaesthesia (UGRA) as a standard of care in an orthopaedic centre in rural India where it was never used as an anaesthetic technique.

Methods This is a retrospective analysis of 312 patients with upper limb trauma operated under ultrasound guided regional anaesthesia (UGRA) between January 2022 to April 2023. We assessed the effectiveness of the block using pain scores at rest and on movement, the need for rescue anaesthesia and perioperative outcome in these patients.

Results A total of 312 patients received UGRA in this study. 58% of the patients were ASA grade 1 and 2. 42% patients came under ASA grade 3 and 4. 30% patients from ASA 1 and 2 categories required additional conscious sedation in the intraoperative period. However, none of the patients from the ASA 3 and 4 required any sedation and were done solely under USGRA.

Conclusions 1. USGRA proves to be a safe and reliable choice of anaesthesia in high risk cases if appropriate equipments and expertise are available. 2. Confidence, Competence and Conviction can help this state of art technique to penetrate in areas where it has still not found its way.

#36405 THE PARAVERTEBRAL SPACE: AN UNEXPECTED DISGUISE

¹Bandopadhyay Rahul*, ²Federico Femia, ¹Cheng Ong. ¹Department of Anaesthetics, Guy's and St Thomas' NHS Foundation Trust, London, UK; ²Department of Thoracic Surgery, Guy's and St Thomas' NHS Foundation Trust, London, UK

10.1136/rapm-2023-ESRA.661

Please confirm that an ethics committee approval has been applied for or granted: Not relevant (see information at the bottom of this page)

Application for ESRA Abstract Prizes: I apply as an Anaesthesiologist (Aged 35 years old or less)

Background and Aims The presence of a pleural effusion can present challenges during the performance of paravertebral block (PVB) under ultrasound (US). PVB is a regional anaesthetic technique used in thoracic surgery for perioperative and postoperative analgesia. In our centre, we have performed PVB in patients with pleural effusions undergoing pleural

drainage and diagnostic video-assisted thoracoscopic surgery. In doing so, we have discovered that the US image of the chest is altered in these patients. We wish to demonstrate this finding as it affects the performance of a successful PVB.

Methods Patients with a pleural effusion undergoing thoracic surgery underwent a US-guided PVB in sagittal orientation with a 12MHz linear transducer. Images were taken before and after PVB injection of local anaesthetic (LA).

Results On US imaging, the presence of a pleural effusion has the appearance of the paravertebral space on first inspection: a dark hypoechoic space bounded by 'bright' pleural borders. In one patient this was confirmed by inadvertent aspiration of pleural fluid. On closer inspection, the paravertebral space is more superficial and hyperechoic than normally anticipated. The injection of LA injection into the true paravertebral space renders the borders more prominent.

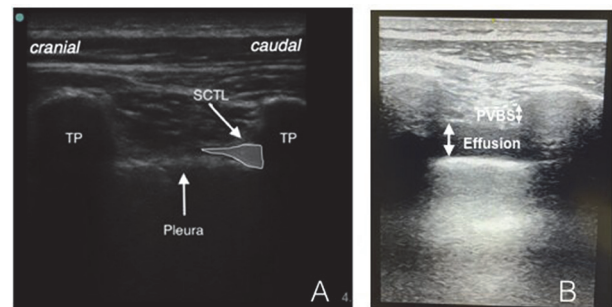


Fig 1. US sagittal view of paravertebral block anatomy. A) Typical sonoanatomy for PVB. B) Sonographic appearances of PVB with presence of pleural effusion (post LA injection); TP (transverse process), PVBS (paravertebral space), SCTL (superior costotransverse ligament). Dashed white line denotes SCTL.

Abstract #36405 Figure 1 US sagittal view of PVB anatomy comparing normal (A) with pleural effusion (B)

Conclusions We demonstrate that a pleural effusion may be mistakenly identified as the paravertebral space when performing an US-guided PVB. The true paravertebral space is more superficial and becomes more prominent after injection into the space. Misidentification of the space may result in suboptimal block efficacy, limitation of local anaesthetic spread, inadvertent needling of effusion, haemothorax and infection.

#35972 INTRA-OPERATIVE BLOCKS FOR HIP FRACTURE SURGERY – HOW ARE WE DOING AT OPTIMISING ANALGESIA FOR PATIENTS?

Chao-Ying Kowa*, Simeon West. Department of Anaesthesia, University College Hospital, London, UK

10.1136/rapm-2023-ESRA.662

Please confirm that an ethics committee approval has been applied for or granted: Not relevant (see information at the bottom of this page)

Background and Aims Hip fractures are the commonest reason for older patients presenting for emergency surgery (1) and are extremely painful (2). National guidelines recommend routine performance of supplementary nerve blocks alongside general/spinal anaesthesia (GA/SA respectively) (3). We aimed to evaluate departmental practice and identify areas for improvement.