

**OP005** **COMPARISON OF EFFICACY OF ULTRASOUND GUIDED SERRATUS ANTERIOR PLANE BLOCK VERSUS ERECTOR SPINAE PLANE BLOCK FOR POSTOPERATIVE ANALGESIA AFTER MODIFIED RADICAL MASTECTOMY-A RANDOMIZED CONTROLLED TRIAL**

<sup>1</sup>Vinod Kumar\*, <sup>2</sup>Deepti Ahuja, <sup>1</sup>Nishkarsh Gupta, <sup>1</sup>Sushma Bhatnagar, <sup>1</sup>Seema Mishra, <sup>1</sup>Sachidanand Jee Bharati, <sup>1</sup>Rakesh Garg. <sup>1</sup>Oncoanaesthesia and Palliative Medicine, AIIMS, Delhi, India; <sup>2</sup>Anaesthesiology, RGCIRC, Delhi, India

10.1136/rapm-2023-ESRA.5

Please confirm that an ethics committee approval has been applied for or granted: Yes: I'm uploading the Ethics Committee Approval as a PDF file with this abstract submission

Application for ESRA Abstract Prizes: I apply as a Trainee/ Resident/Fellow (no age limit)

**Background and Aims** Several interfascial plane blocks have been described in patients undergoing modified radical mastectomy (MRM). However, the most efficacious technique is not known. So, we conducted this study to evaluate the analgesic efficacy of ultrasound guided serratus anterior plane (SAP) block and erector spinae plane (ESP) block in patients undergoing MRM.

**Methods** 80 female patients (18-70 years) undergoing MRM were randomized to two groups of 40 each and given ultrasound guided SAP block or ESP block with 0.4ml/kg of 0.375% ropivacaine in this prospective double-blind control trial. The groups were compared for the time to first dose of rescue analgesic, requirement of rescue analgesics and patient satisfaction score.

**Results** The time to first rescue analgesia was significantly prolonged in SAP group as compared to ESP group ( $p=0.03$ ). The probability of a patient being pain-free (NRS<3) was significantly higher in SAP group than ESP group. Postoperative pain scores at rest at 0 minute was significantly lower in SAP group as compared to ESP group. The intraoperative fentanyl

requirement and postoperative diclofenac and tramadol requirements were comparable between the two groups. The number of patients requiring rescue doses of fentanyl intraoperatively and rescue analgesics postoperatively were similar in both the groups. The mean patient satisfaction score was also comparable in both groups.

**Conclusions** Ultrasound guided SAP block significantly prolonged the time to first rescue analgesia and a small trend toward lower requirement of rescue analgesics and better patient satisfaction as compared to ESP block in patients undergoing MRM.

**OP006** **EFFECT ON SACRAL SPREAD OF LOCAL ANESTHETIC WITH 27-G SPINAL NEEDLE DURAL PUNCTURE EPIDURAL ANALGESIA COMPARED TO EPIDURAL ANALGESIA DURING LABOR: A RANDOMISED, CONTROLLED TRIAL**

<sup>1</sup>Nicoletta Filetici\*, <sup>1</sup>Luciano Frassanito, <sup>2</sup>Marc Van de Velde, <sup>3</sup>Lawrence Tsen, <sup>1</sup>Bruno Antonio Zanfini, <sup>1</sup>Stefano Catarci, <sup>1</sup>Mariano Ciancia, <sup>1</sup>Gaetano Draisci. <sup>1</sup>Anesthesia in Obstetrics, Gynaecology and Pain Therapy, IRCCS Fondazione Policlinico Universitario Agostino Gemelli, Rome, Italy; <sup>2</sup>Dept. Anesthesiology, UZ Leuven, Leuven, Belgium; <sup>3</sup>Dept. of Anesthesiology, Brigham and Women's Hospital, Boston, USA

10.1136/rapm-2023-ESRA.6

Please confirm that an ethics committee approval has been applied for or granted: Yes: I'm uploading the Ethics Committee Approval as a PDF file with this abstract submission

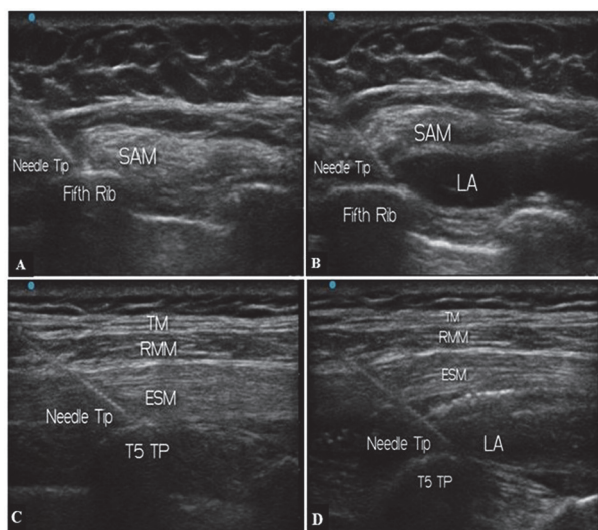
Application for ESRA Abstract Prizes: I apply as an Anesthesiologist (Aged 35 years old or less)

**Background and Aims** The Dural Puncture Epidural (DPE) seems to provide better sacral labor analgesia than the conventional Epidural (EPL) technique when performed with 25 and 26-G spinal needles. This double-blinded randomized controlled trial aims to investigate whether a 27-G needle DPE results in faster bilateral sacral blockade compared to EPL.

**Methods** Following ethics approval and written consent, 108 nulliparous women were included. 54 patients received a conventional EPL, while the DPE group (n=54) received a needle-through-needle dural puncture technique using a 27-G Whitacre needle. In both groups analgesia was initiated epidurally with 15 mL of ropivacaine 0.1% and sufentanil 0.5 mcg mL<sup>-1</sup> and maintained with 10 ml bolus of the same mixture provided hourly through a Programmed Intermittent Epidural Bolus infusion. Bilateral sacral blockade was tested at the S2 dermatomes using a pin-prick examination 10 minutes after analgesia completion, then at pre-defined intervals until delivery.

**Results** Time to bilateral sacral blockade was significantly different in the two groups (hazard ratio 0.30, 95% confidence interval [CI] 0.19 to 0.48,  $P<0.001$ ). One hour after analgesia initiation 94% DPE patients achieved bilateral sacral blockade compared to 63% of the EPL group ( $P<0.001$ ), with greater results at 10 minutes (risk ratio [RR] 3.00, 95% CI 1.69 to 5.29;  $P<0.001$ ) and at 20 minutes (RR 2.38, 95% CI 1.35 to 4.21;  $P=0.001$ ).

**Conclusions** Within 1 hour after initiation of neuraxial analgesia, the DPE technique using a 27-G Whitacre spinal needle provides an improved S2 dermatomes coverage compared to EPL.



USG images

A, B- SAP block showing needle tip and drug deposited  
C, D- ESP block with needle tip and drug deposited

**Abstract OP005 Figure 1** USG images showing needle tip and drug deposition in SAP and ESP block