

EP216 EPIDURAL LABOUR ANALGESIA IS NOT ALWAYS CONTRAINDICATED IN PATIENTS WITH SPINAL DYSRAPHISM: A TETHERED CORD SYNDROME CASE REPORT

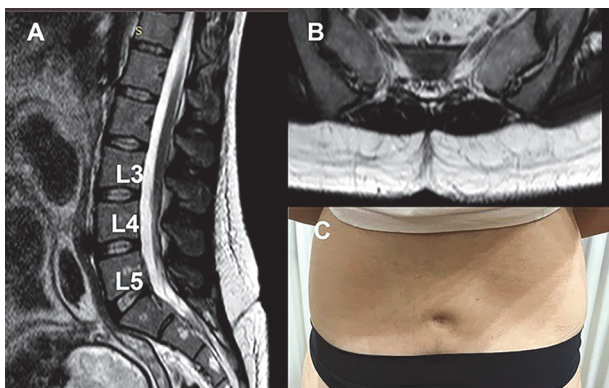
¹Cristina Todde, ¹Marco Aversano*, ²Leoni Matteo Luigi Giuseppe, ³Antonina Zagari, ⁴Laura Feole, ³Maria Grazia Frigo. ¹Interdepartmental Unit of Obstetric Anaesthesia and Intensive Care – Department of Emergency, Fatebenefratelli – Isola Tiberina Gemelli Isola Hospital, Roma, Italy; ²Unit of Interventional and Surgical Pain Management, Guglielmo da Saliceto Hospital, Piacenza, Italy; ³Interdepartmental Unit of Obstetric Anaesthesia and Intensive Care – Department of Emergency, Fatebenefratelli – Isola Tiberina Gemelli Isola Hospital, Rome, Italy; ⁴Unit of Gynecology, Campus Biomedico University, Roma, Italy

10.1136/rapm-2023-ESRA.276

Background and Aims Spinal dysraphism is a heterogeneous group of vertebral arches disorders with direct implications for the peripartum anaesthetic care. In fact, even if labour analgesia is a common regional anaesthetic technique to provide pain relief during labour, the presence of spinal dysraphism generally contraindicates the use of neuraxial approaches.

Methods We present the case of a 30-year-old female, ASA 2, who presented to our department at 38 weeks of gestation for pre-operative evaluation. During the clinical evaluation, a skin dimple was noted in the sacral area and no visible scoliosis was identified. An accurate neurological examination was completely negative without any related symptoms. A lumbar magnetic resonance imaging (MRI) revealed a tethered cord syndrome with an interrupted sacral posterior neural arch located at S2 and associated with an abnormally low positioned conus medullaris (figure 1).

Results Epidural analgesia was selected to avoid a possible spinal cord injury using combined spinal-epidural technique. Consequently, an epidural catheter was inserted at L2-L3 level and 10mcg epidural sufentanyl bolus followed by intermittent top-up 15-20ml ropivacaine 0.1-0.2% injections allowed an optimal pain management during the labour. No complications and adverse effects occurred in the postpartum period.



Abstract EP216 Figure 1 Sagittal (A) and axial (B) T2 weighted MRI of the lumbar spine showing an abnormally low positioned conus medullaris (L4-L5) associated with interrupted sacral posterior S2 neural arch corresponding to a skin dimple (C)

Conclusions This case suggests that a proper evaluation of spinal dysraphism is a key element to improve the labour's anaesthetic management and for determining the feasibility of neuraxial analgesia. In fact, labour analgesia can be safely performed in well selected patients with tethered cord syndrome.

ePoster session 7 – Station 1

EP217 PATIENT PERSPECTIVES OF INFORMED CONSENT FOR REGIONAL ANESTHESIA FOR AMBULATORY SURGERY

¹Liem Ho*, ¹Vishal Uppal, ¹Jon Bailey, ²Akua Gyambibi. ¹Dalhousie University: Department of Anesthesia, Halifax, Canada; ²University of Alberta: Department of Anesthesia, Edmonton, Canada

10.1136/rapm-2023-ESRA.277

Background and Aims Risks and benefits associated with peripheral nerve blockade (PNB) are often discussed between anesthesiologists and patients before surgery. The aim of the study is to determine how patients who had the option of having a PNB for surgical anesthesia felt about the informed consent discussions they had with their anesthesiologist and which parts of these discussions were most beneficial.

Methods Patients who underwent ambulatory upper extremity surgery amenable to brachial plexus block (BPB) for surgical anesthesia were identified through the block room records. Patients were contacted by phone after discharge. If agreeable, a qualitative, semi-structured one-on-one interview was completed 1-4 weeks following surgery. Audio of the interviews were recorded and transcribed into de-identified versions for analysis. A team-based approach was used to analyze the transcripts using thematic analysis.

Results Thematic saturation was reached at 15 patients. All 15 patients had undergone a BPB for surgical anesthesia. No patients who declined a BPB agreed to participate. The results showed there was overall satisfaction with the consent for a PNB. Interviewees thought that good consent should include a detailed description of the patients' experience, a relaxed and reassuring bedside manner, a discussion of specific risks, description of the benefits, personalized advice based on prior experience, and the use of supplemental visual materials. Participants described reassurance or potential to be reassured if they were informed about the block process.

Conclusions Patients emphasized that strong consent procedures include many other aspects outside of a description of risks.

EP218 CAUDAL EPIDURAL BLOCK VERSUS ANTERIOR QUADRATUS LUMBORUM BLOCK FOR PEDIATRIC HIP SURGERY

Marwa Mejri, Dorra Boukottaya, Chadha Ben Messaoud*, Yasmine Trabelsi, Oussama Nasri, Emna Trigui, Olfa Kaabachi. *Anesthesiology, institut kassab, Tunis, Tunisia*

10.1136/rapm-2023-ESRA.278

Background and Aims In hip dislocation surgery, adequate analgesia is crucial for early rehabilitation. Anterior quadratus lumborum block (AQLB) may be superior to caudal epidural block (CB) for analgesia in hip surgery with fewer complications. In this study, we aimed to confirm superiority of AQLB compared to CB in children for analgesia in open hip surgery.

Methods We conducted a double-blind study with 40 patients aged 2-7 years, undergoing unilateral open hip surgery and randomized into two groups. Ultrasound blocks were performed using 1 ml/kg Ropivacaine 0.2%. All patients had Paracetamol every six hours. Tramadol was planned as rescue analgesia when CHEOPS score was >6(2mg/kg). The primary outcome was the total consumption of analgesics in the first