

within the first week and improvement of pain by 90% was recorded by 179 (179/219, 82%) within the first month. Side effects were light to moderate and limited after the first 4–5 days. Improvement in sleep quality was the reported in 90% of the cases.

Conclusions Almost 37% of patients with CLBP had NC. The use of pregabalin in CLBP patients with NC is an effective and safe treatment.

Ultrasound guided RA (UGRA)

B14 ULTRASOUND-GUIDED TRANSVERSALIS FASCIA PLANE BLOCK REDUCES POSTOPERATIVE PAIN INTENSITY IN PEDIATRIC PATIENTS UNDERGOING APPENDICITIS

¹Y Semkovych*, ²D Dmytriv. ¹Ivano-Frankivsk National Medical University, Ivano-Frankovsk, Ukraine; ²Vinnitsa National Medical University, Vinnitsa, Ukraine

10.1136/rapm-2022-ESRA.89

Background and Aims Early postoperative reduction of hospital stay necessitate efficient postoperative analgesia. Transversalis fascia plane block (TFPB) has provided adequate analgesia and lowered postoperative opioid requirement in comparison to controls for some abdominal surgery.

Methods After LEC approval trial a 37 children (14.4 ± 2.1 years) undergoing appendicitis were randomized to receive 0.33% ropivacaine (Group TFPB, $n = 24$) or saline (Group Control, $n = 23$) for TFP block. Spinal anesthesia was then performed. Pain intensity was assessed using the visual analog scale (0: no pain to 10: worst possible pain). The primary outcome was pain scores recorded at rest at 3, 6, 12, 24, 36, and 48 h and on standing and walking at 24, 36, and 48 h postoperatively. Secondary outcomes were analgesic consumption, side effects, and patient satisfaction after surgery.

Results Postoperative pain intensity was significantly lower in Group TFPB compared to Group Control at rest after 3, 6, 12, 24, 36, and 48 h ($p < 0.001$) and during mobilization after 24, 36, and 48 h ($p < 0.001$). Morphine use was significantly lower in Group TFPB compared to Group Control during 0–24 h (14.4 ± 5.2 vs. 29.1 ± 7.3 mg, $p < 0.001$) and during 24–48 h (12.1 ± 3.2 vs. 18.3 ± 5.2 mg, $p < 0.001$) postoperatively. Incidences of nausea (4,4% vs. 21,2%, $p=0.006$), vomiting (6,8% vs. 22,2%, $p = 0.022$), and urinary retention (9,8% vs. 28,6%, $p=0.030$) were lower in Group TFPB than in Group Control.

Conclusions Ultrasound-guided TFPB block is an effective pain management technique after abdominal surgery in children.

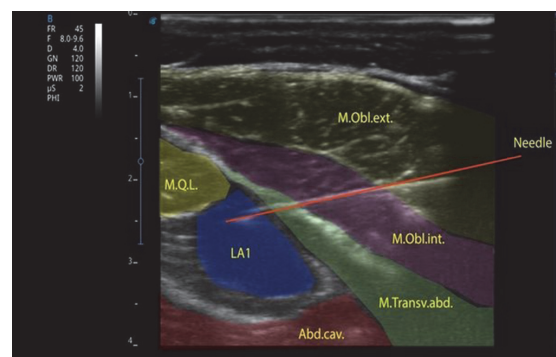
B15 ULTRASOUND-GUIDED TRANSVERSALIS FASCIA PLANE BLOCK FOR POSTOPERATIVE PAIN CONTROL IN PEDIATRIC PATIENTS UNDERGOING UNILATERAL INGUINAL HERNIA REPAIR, A COMPARATIVE STUDY BETWEEN TWO APPROACHES

¹D Dmytriv, ²Y Semkovich*. ¹Vinnitsa National Medical University, Vinnitsa, Ukraine; ²Ivano-Frankivsk National Medical University, Ivano-Frankovsk, Ukraine

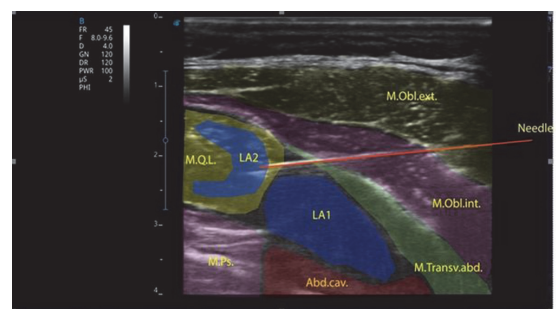
10.1136/rapm-2022-ESRA.90

Background and Aims Early postoperative ambulation and reduction of hospital stay necessitate efficient postoperative analgesia. Transversalis fascia plane block (TFPB) has been described to provide adequate postoperative analgesia after abdominal surgery. This randomized comparative trial was designed to compare the duration of analgesia provided by two different TFPB approaches; the TFPB and intramuscular QLB + TFPB in patients undergoing surgical repair of unilateral inguinal hernia.

Methods 27 patients, aged from 12 to 18 years, ASA physical status I or II, scheduled for unilateral inguinal hernia repair were enrolled. At the end of the surgical procedure and before recovery from general anesthesia, Patients were randomly assigned into two groups to receive either TFPB (Group TFPB) (figure 1) or intramuscular QLB+TFPB (Group Q+TFPB) (figure 2) using 10 ml 0.25% bupivacaine. Duration of analgesia, postoperative VAS and postoperative opioid consumption were recorded.



Abstract B15 Figure 1 TFPB standard approaches.



Abstract B15 Figure 2 Q+TFPB approaches.

Results Duration of block was significantly longer in Q+TFPB group when compared to TFPB group ($22.1 + 3.4$ h versus $11.8 + 4.8$ respectively) with P value of < 0.001 . A statistically significant lower VAS score was recorded in Q+TFPB group immediately and 12 h postoperative. Q+TFPB group showed a statistically significant delayed time of first analgesic request and less postoperative morphine consumption with P value of < 0.001 and 0.001 respectively.

Conclusions Ultrasound guided postsurgical intramuscular QLB + TFPB using 10 ml 0.25% bupivacaine produces more postoperative analgesic effect and less postoperative opioid consumption when compared to intramuscular TFPB in patients underwent unilateral inguinal hernia repair under general anesthesia.