

B88

### COMPARISON OF SUPRAINGUINAL FASCIA ILIACA BLOCK WITH CONTROL GROUP IN PATIENTS UNDERGOING TOTAL HIP ARTHROPLASTY: A RANDOMIZED, CONTROLLED STUDY

<sup>1</sup>M Eidininkienė\*, <sup>1,2</sup>A Gelmanas, <sup>1</sup>G Aldakauskaitė. <sup>1</sup>Lithuanian University of Health Sciences, Kaunas, Lithuania; <sup>2</sup>Hospital of Lithuanian University of Health Sciences Kaunas Clinics, Kaunas, Lithuania

10.1136/rapm-2022-ESRA.163

**Background and Aims** Postoperative pain management after major orthopedic surgeries such as total hip arthroplasty (THA) is one of the biggest considerations [1]. Suprainguinal fascia iliaca block (SFIB) might be beneficial for postoperative pain control after THA, but the value persists controversial [2]. This prospective, randomized, double-blinded study aimed to investigate the analgesic efficiency of SFIB after THA compared to control group (C).

**Methods** LUHS Bioethics Committee granted the research (No. BEC-MF-250). 36 patients scheduled for THA were randomized into two groups: 16 in SFIB and 20 in C group. After the operation, a blinded observer recorded pain, extent of motor block (Bromage scale), opioid consumption and additional painkillers. Evaluation of pain: at 3, 6, 24 and 48 hours postoperatively, patients were assessed using a visual analog scale (VAS) on the operated leg at rest, in active and passive 45° flexion positions.

**Results** 36 patients were assessed, 19 (52,8%) men and 17 (47,2%) women. There were no differences between the groups with respect to demographics. Opioid consumption after 24 hours postoperatively was reduced in SFIB group, unfortunately not statistically significantly ( $p > 0,05$ ). The VAS scores at rest and in motion also were similar at all-time points as well as the extent of motor block. Consumption of additional painkillers was less after 24 hours in SFIB (38,9%) than C (50%) and after 48 hours SFIB (27,8%), C (44,4%) but statistically insignificant ( $p > 0,05$ ).

**Conclusions** We conclude that postoperative pain management with SFIB may be valuable after THA. However, a larger study is needed to make the data more reliable.

B89

### CLAVIPECTORALIS FASCIA BLOCK (CPB) COMBINED WITH SUPERFICIAL CERVICAL PLEXUS BLOCK. CASE SERIES FOR CLAVICLE FRACTURE SURGERY

<sup>1</sup>A Santos Macias\*, <sup>2</sup>J Nieto Muñoz, <sup>2</sup>L Valdes Vilches, <sup>2</sup>M Caballero Dominguez, <sup>2</sup>JA Reinaldo Lapuerta. <sup>1</sup>Hospital Costa del Sol, Marbella, Spain; <sup>2</sup>Hospital Costa Del Sol, Marbella, Spain

10.1136/rapm-2022-ESRA.164

**Background and Aims** Clavicle fractures have a relatively low incidence. They account for 2–3% of all fractures and around 35% of those of the shoulder girdle. Among the different types of fractures, 80% occur in the middle third of the clavicle. Given the rise of ultrasound-guided peripheral blocks, led by the clavipectoral fascial plane block (CPB), allow more interesting analgesic options than the classic interscalene block.

**Methods** About 5 cases of clavicle fractures. All the patients were between 28 - 42 years, ASA I except for one patient ASA II due to obesity type I.

All 5 cases were scheduled surgery for open osteosynthesis due to fracture-dislocation of the acromioclavicular joint.

It was performed a balanced general anaesthesia combined with CPB block at mid-clavicular level and superficial cervical plexus block was performed. There were not found any adverse effects or anaesthetic complications. The dose administered was 15 ml of bupivacaine 0.5% for CPB and 5 ml of bupivacaine 0.5% for the superficial cervical plexus block.

**Results** This block allows anaesthesia of the entire clavicle without blocking the brachial plexus. The clavipectoralis fascia surrounds the clavicle in almost its entirety, and the injection underneath the clavicle is able to block the terminal branches that innervate the clavicle. This offers a valid analgesic alternative, which combined with the blockade of the superficial cervical plexus, provides total analgesic coverage for clavicular surgery.

**Conclusions** CPB associated with superficial cervical plexus block is an effective analgesic alternative for clavicular surgery, avoiding brachial plexus block.

B90

### INTER-FASCIAL SPACE BETWEEN SARTORIUS MUSCLE AND FEMORAL ARTERY – ISAFE: NOVEL APPROACH FOR ADDUCTOR CANAL CATHETER – ACC

<sup>1</sup>T Alekberli\*, <sup>1</sup>H dos Santos Fernandes, <sup>1</sup>N Siddiqui, <sup>1</sup>S Peacock, <sup>1</sup>E Vidal, <sup>2</sup>J Wolfstadt, <sup>1</sup>Y Gleicher. <sup>1</sup>Department of Anesthesia and Pain Management, University of Toronto, Toronto, Canada; <sup>2</sup>Department of Orthopedic Surgery, University of Toronto, Toronto, Canada

10.1136/rapm-2022-ESRA.165

**Background and Aims** We propose the ISAFE technique for ACC placement ( Figures - 1 & 2 ) to avoid the proximity of catheter tip to Femoral Vein-FV, an accidental venous-puncture, reduce potential trauma to saphenous nerve - SN, and prevent ACC - dislodgement.

**Methods** ACC were inserted in sixteen total knee arthroplasty (TKA) patients postoperatively to avoid ACC displacement by the intraoperative thigh-tourniquet.

5 mL/h disposable elastomeric infusion-pump (Baxter-International-Inc.,IL,US) of 250 ml- Ropivacaine 0.2% infused over 48 hours-outpatient setting.

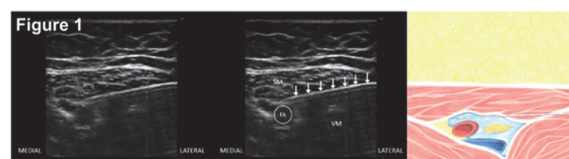
The ISAFE approach:

**Needle insertion:** level of the mid-adductor canal, mid-sartorius, in-plane (lateral to medial)

**Needle advancement:** piercing through the posterior fascia of Sartorius muscle-SM approximately 1–2 cm lateral to Femoral Artery-FA, entering adductor canal (Figure 1).

**ISAFE hydro-dissection:** Needle angle is then decreased to avoid FV and advanced into the inter-fascial space between FA and SM (Figure 1). Hydro-dissection is necessary to open the inter-fascial space and separating FA from SM.

**Catheter insertion at the 11 o'clock position** anteromedial position to FA, facilitating over-threading catheter (Figure-2). We recommend threading the catheter approximately 3–5 mm past FA.



Abstract B90 Figure 1