

# Analgesia and anesthesia using the pericapsular nerve group block in hip surgery and hip fracture: a scoping review

Craig Morrison ,<sup>1</sup> Brigid Brown,<sup>1</sup> D-Yin Lin,<sup>1</sup> Ruurd Jaarsma,<sup>2</sup> Hidde Kroon<sup>3,4</sup>

► Additional material is published online only. To view, please visit the journal online (<http://dx.doi.org/10.1136/rapm-2020-101826>).

<sup>1</sup>Anesthesiology, Flinders Medical Centre, Bedford Park, South Australia, Australia

<sup>2</sup>Orthopaedics and Trauma Surgery, Flinders Medical Centre, Bedford Park, South Australia, Australia

<sup>3</sup>Surgery, Royal Adelaide Hospital, Adelaide, South Australia, Australia

<sup>4</sup>Faculty of Health and Medical Sciences, The University of Adelaide, Adelaide, South Australia, Australia

## Correspondence to

Dr Craig Morrison, Anesthesiology, Flinders Medical Centre, Bedford Park, SA 5042, Australia; [craig.morrison@sa.gov.au](mailto:craig.morrison@sa.gov.au)

Received 15 June 2020

Revised 21 September 2020

Accepted 26 September 2020

Published Online First

27 October 2020

## ABSTRACT

**Introduction** Pericapsular nerve group (PENG) block is a novel regional analgesia technique to reduce pain after hip surgery and hip fractures. This review was conducted to summarize current literature.

**Methods** A scoping review was carried out using the Joanna Briggs Institute framework. All articles describing the use of PENG block as a regional analgesia and/or anesthesia technique for hip pain were considered eligible for inclusion. Ovid Medline, Embase, CINAHL, PubMed and Google Scholar were searched. Adult and pediatric studies were included. Excluded were articles not available in English language, not available in full-text, related to non-orthopedic indications such as soft tissue surgery, and pelvic or femoral shaft fractures.

**Results** Database searches identified 345 articles, 20 of which could be included in the current review, with a combined patient number of 74. Included articles comprised case reports and case series only, describing 1 to 10 patients. In all studies, PENG block was described to provide sufficient analgesia or anesthesia. Transient motor side effects occurred only when the local anesthetic was deposited in an unintended location (n=2).

**Conclusions** Current evidence of using PENG block for hip surgery or hip pain is limited to case reports and case series only. PENG block is a promising regional analgesia technique as an alternative to other regional nerve blocks such as femoral nerve block or iliac fascia nerve block. Observational and experimental studies are required to determine the effectiveness, efficacy and safety of the PENG block.

## INTRODUCTION

Effective regional analgesia for pain originating from the hip after a fracture or during surgery can be described as elusive.<sup>1</sup> A variety of regional analgesia techniques, such as femoral nerve block, iliac fascia block and psoas compartment block, are used regularly. The recent Cochrane review on these regional analgesia techniques demonstrated an average pain score reduction of 3.4 points on a 10-point Numerical Rating Scale, 30 min after placement.<sup>1</sup> Although this is a statistically significant reduction in pain exceeding the minimal clinically important difference,<sup>2</sup> international guidelines question whether reductions from currently broadly used nerve blocks are clinically relevant when compared with systemic analgesia in the context of patients with a fractured neck of femur.<sup>3</sup>

One of the difficulties of effective regional analgesia for hip pain is the complex innervation of the joint as it comes from multiple nerves. In an anatomical study, Short *et al*<sup>4</sup> demonstrated that sensory innervation of the anterior capsule of the hip includes articular branches of the femoral, obturator and accessory obturator nerve. They also showed that the ‘high’ branches of the femoral nerve play a greater role in the sensory innervation of the anterior hip capsule than previously appreciated. In almost all cadavers examined (92%), the femoral nerve had ‘high’ sensory articular branches cranially to the inguinal ligament, making it difficult to block this nerve with infra-inguinal techniques such as the iliac fascia block or femoral nerve block.<sup>4</sup> Furthermore, it has been demonstrated that techniques, such as the iliac fascia block, often fail to adequately block the obturator nerve, which also provides sensory innervation to the anterior hip capsule.<sup>4</sup> Triggered by these findings, in 2018 Giron-Arango *et al*<sup>5</sup> described the pericapsular nerve group (PENG) block for the first time using a low-frequency curvilinear ultrasound probe to deposit local anesthetic in the musculofascial plane between the psoas tendon anteriorly and the pubic ramus posteriorly. In their hands, PENG block in patients with hip fractures reduced pain scores by a median of 7 points on a 10-point Numerical Rating Scale, without causing motor block.<sup>5</sup>

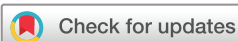Given the recent introduction of PENG block, literature describing its safety and efficacy is limited with no review articles available yet. Therefore, we conducted the current scoping review with the goal to map current literature for PENG block as a regional analgesia or anesthesia technique in patients with hip pain encompassing both patients with hip fractures and those undergoing hip surgery.

## METHODS

### Search strategies and terms

A comprehensive systematic review of literature was conducted according to the Preferred Reporting Items for Systematic Reviews and Meta-Analyses (PRISMA) guidelines using the framework recommended by the Joanna Briggs Institute.<sup>6</sup> The study methods were established prior to conducting the review.

The key search terms were ‘pericapsular nerve group block’, ‘autonomic nerve block’, ‘nerve block’, ‘plane block’, ‘PENG’, ‘supra-inguinal iliac fascia.’ A complete list of the search terms is listed in online supplemental appendix A. The search



© American Society of Regional Anesthesia & Pain Medicine 2021. No commercial re-use. See rights and permissions. Published by BMJ.

**To cite:** Morrison C, Brown B, Lin D-Y, *et al*. *Reg Anesth Pain Med* 2021;**46**:169–175.

terms were joined by Boolean operators. The search strategy was created with the assistance of a clinical librarian (NM) at our institution.

Ovid MEDLINE, Excerpta Medica dataBASE (EMBASE), PubMed, Cumulative Index to Nursing and Allied Health Literature (CINAHL), Cochrane database of systematic reviews and Google Scholar databases were searched independently by two authors (CM and BB) for all publication types, with the last search conducted on April 13, 2020.

### Eligibility criteria

Articles eligible for inclusion were those written in English language, describing the use of PENG block in adult or pediatric patients, in the context of pain originating from the hip caused by either fracture or surgery. The hip was considered as the articulation between the acetabulum and the proximal femur (head-neck-trochanter). There were no restrictions in the included number of patients. Search was conducted for articles published from January 2018 onward, given the date of the inaugural publication describing PENG block. Excluded were studies describing the use of PENG block for other indications (such as femoral shaft fractures, pelvic fractures, periprosthetic femoral fractures, urological, soft tissue or vascular surgery), studies not

available in English language and studies for which full-text was not available.

### Article selection and inclusion

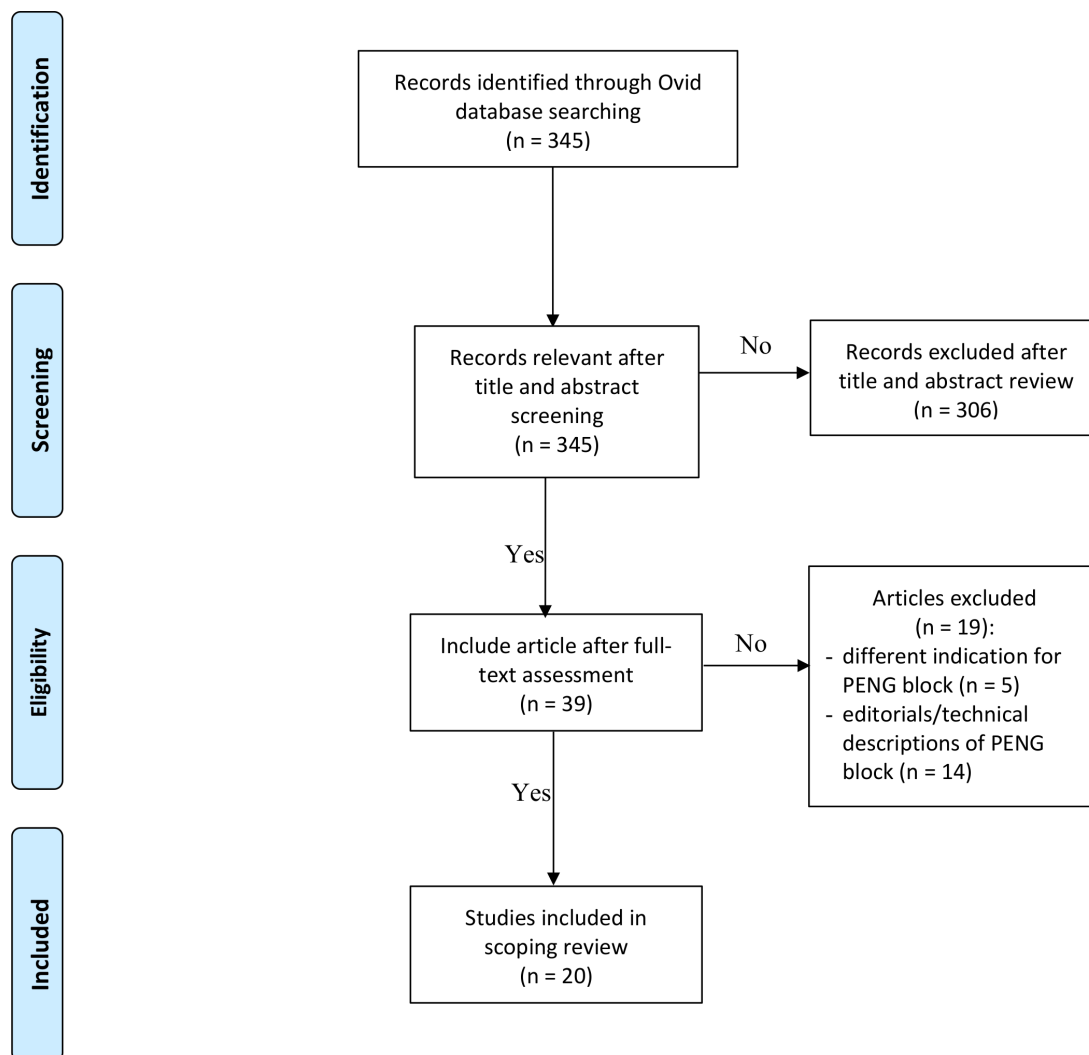
Two authors (CM and BB) independently screened titles and abstracts of the search results selecting articles for full-text review, which described the use of PENG block in adult or pediatric patients, in the context of pain originating from the hip caused by either fracture or surgery (figure 1).

Next, full-text review of potentially relevant articles was performed by the same two authors. Reference lists of articles selected for full-text assessment were reviewed for potentially additional articles of relevance.

A third author (D-YL) was consulted to mediate discussion in the event of disagreement.

### Data extraction and quality assessment

The following data were extracted by the two authors (CM and BB) to a predefined extraction chart from the included articles: author, year of publication, country of origin, type of publication (case report/case series), number of included patients, adult or pediatric study population, setting (hip fracture analgesia/hip



**Figure 1** Preferred Reporting Items for Systematic Reviews and Meta-Analyses (PRISMA) flowchart for selection of studies for the current review. PENG, pericapsular nerve group.

surgery postoperative analgesia/hip relocation/anesthesia/other), PENG block technique (ultrasound probe type, local anesthetic solution used, use of a nerve catheter), additional analgesia used, analgesia outcomes and adverse events.

## RESULTS

Database screening yielded 345 articles, of which 20 articles met the inclusion criteria, with a total number of 74 patients. All 20 articles were case reports or case series, published between November 2018 and April 2020 and summarized in [table 1](#). A flowchart of article selection is shown in [figure 1](#). Articles identified for inclusion originated from Canada, India, Turkey, Saudi Arabia, Costa Rica, Nepal, Italy, Spain, Colombia and Portugal.

### Analgesic outcomes

#### PENG block in isolation

The use of PENG block as a regional analgesia technique without other nerve blocks has been described in 11 studies, in a total of 35 adult patients and one pediatric patient, in a variety of settings including hip relocation, hip fracture analgesia and hip surgery.<sup>5–7–16</sup> The included studies reported that PENG block provides analgesia in these settings, with reduced or no need for oral or intravenous opioid analgesia. In one study, including a total of five patients, it was reported that after hip fracture surgery a few of the patients experienced pain in the distribution of the lateral femoral cutaneous nerve.<sup>9</sup>

#### PENG block in combination with other regional analgesia techniques

PENG block in combination with local anesthetic infiltration, or other nerve blocks such as femoral nerve block or lateral femoral cutaneous nerve block, has been described in nine studies in a total of 32 adult patients and one pediatric patient.<sup>9–17–22</sup> These patients underwent hip arthroscopy, hip arthroplasty, hip fracture surgery or removal of osteosynthetic material. All reports indicated sufficient analgesia with no to minimal opioid requirements up to 72 hours postoperatively.

In three hip arthroplasty patients, PENG block was combined with a lumbar level erector spinae plane block. In these patients, the maximum reported pain score 24 hours postoperatively was 3/10 with a maximum use of 8 mg intravenous morphine equivalents.<sup>23</sup> The combination of PENG block and lumbar erector spinae block was also reported in one pediatric patient undergoing surgery for congenital hip dysplasia with a maximum postoperative pain score of 1/10 and no requirement for additional postoperative opioid analgesia.<sup>24</sup>

### Anesthesia outcomes

Notably, PENG block was used as the sole anesthetic technique for hip relocation in two adult patients, without requiring general anesthesia, neuraxial anesthesia or sedation.<sup>25</sup>

### Technical aspects of PENG block

Varying techniques have been described with 10 studies reporting the use of curvilinear low-frequency ultrasound probes, four using linear high-frequency ultrasound probes and six studies not stating what type of ultrasound probe was used. No study compared the effect of different ultrasound probe selection.

In 19 studies, patients received single-shot nerve blocks except for the study by Santos *et al.*,<sup>16</sup> who described the use of a continuous nerve catheter and local anesthetic infusion in a single adult patient undergoing hip arthroplasty. This patient required no further analgesia for up to 72 hours postoperatively.

No study reported the effective duration of PENG block, the effect of varying local anesthetic concentrations or the effect of additives in the local anesthetic solutions.

### Motor weakness

One study reported two patients who experienced quadriceps muscle weakness after PENG block. PENG block placement was technically difficult in both patients, likely resulting in femoral nerve block caused by deposition of local anesthetic outside of the PENG block anatomical location in the musculo-fascial plane between the psoas tendon anteriorly and the pubic ramus posteriorly.<sup>8</sup> In both patients, the quadriceps weakness resolved within 48 hours.

### Adverse events

None of the studies reported any local anesthetic systemic toxicity, anaphylaxis, permanent nerve injury or other serious adverse events after PENG block.

## DISCUSSION

In this first scoping review of PENG block as regional analgesia or anesthesia technique for pain originating from the hip, we found that there is currently insufficient evidence to recommend PENG block. Within the limitations of current evidence, PENG block may provide analgesia, but since to date literature is limited to case reports and case series only, there is a high risk of publication bias, making it hard, if not impossible comment on safety and efficacy.

In theory, PENG block has potential advantages over traditional forms of regional analgesia for pain originating from the hip, such as femoral nerve or fascia iliaca blocks. One of these potential advantages includes a wider and more complete coverage of sensory nerves innervating the hip, leading to more effective regional analgesia with the potential to reduce postoperative pain. This may lead to increased patient satisfaction and reduced postoperative opioid consumption, potentially causing less opioid-related adverse events and fewer patients with long-term opioid dependency, as this can be triggered after a prescription from a medical professional.<sup>26</sup> Furthermore, if studies with large patient numbers confirm the absence of motor blockage after PENG block, it may allow early patient mobilization and participation in rehabilitation, contributing to an early recovery. The currently available reports are insufficient to comment on PENG block as a sole anesthesia technique for hip relocation or other procedures.

The easily identifiable sonographic landmarks of the anterior inferior iliac spine, the iliopubic eminence and the psoas tendon make the technical performance of PENG block comparable with other nerve blocks at the least.<sup>5</sup> This is supported by current literature not describing any serious adverse events after PENG block such as permanent nerve injury, major vascular damage or local anesthetic systemic toxicity, although it has to be borne in mind that current literature is too limited to conclude this. Additionally, several concerns have been raised regarding the safety of PENG block.<sup>27</sup> For instance, performing PENG block in patients with coagulation disorders or those on anticoagulant medication could potentially be dangerous.<sup>27</sup> Furthermore, when performing PENG blockage there is potential for the needle path to transverse either the femoral nerve or the lateral femoral cutaneous nerve.<sup>27</sup> In the current review, two patients experienced femoral nerve block after PENG block. In these patients, however, it was suspected that the local anesthetic agent was deposited in a different anatomical location, since the femoral nerve blockage

**Table 1** Summary of literature of PENG block for hip pain

First author, publication date, country (reference)	Type of report	Setting	Number of patients	Intervention	Additional nerve blocks used
<b>PENG block in isolation for analgesia</b>					
Giron-Arango L, Nov-18, Canada <sup>5</sup>	Case series	Hip fracture analgesia	Five adults	PENG block with either 20 mL of 0.25% bupivacaine with 1:400 000 epinephrine or 20 mL of 0.5% ropivacaine with 1:200 000 epinephrine plus 4 mg dexamethasone	None
Mistry T, Mar-19, India <sup>7</sup>	Case series	Hip fracture analgesia	Five adults	PENG block (local anesthetic solution not specified)	None
Yu HC, May-19, Canada <sup>8</sup>	Case report	Hip fracture surgery	Two adults	PENG block with either 20 mL 0.25% or 0.5% bupivacaine and 1:400 000 epinephrine+50 mcg/mL dexamethasone	None
Roy R, Jun-19, India <sup>9</sup>	Case series	Hip fracture surgery	Five patients initially—age not stated	PENG block—local anesthetic solution not described	None
Rocha Romero A, Jun-19, Costa Rica <sup>10</sup>	Case report	Hip fracture analgesia	One adult	PENG block with neurolytic injection of 10 mL of 6% phenol	None
Ueshima H, Sep-19, Japan <sup>11</sup>	Case report	Hip arthroplasty	Two adults	PENG block with 20 mL of 0.25% levobupivacaine	None
Acharya U, Mar-19, Nepal <sup>12</sup>	Case series	Hip fracture analgesia	Ten adults	PENG block with 20 mL 0.125% bupivacaine and 4 mg dexamethasone	None
Ahiskalioglu A, Nov-19, Turkey <sup>13</sup>	Case report	Hip fracture analgesia	One adult	PENG block with 15 mL 0.5% bupivacaine and 15 mL 2% lignocaine	None
Bilal, Jan-20, Turkey <sup>14</sup>	Case report	Hip fracture surgery	Two adults	PENG block with 30 mL 0.25% bupivacaine	None
Aksu C, May-20, Turkey <sup>15</sup>	Case report	Open reduction congenital hip dysplasia	One pediatric	PENG block with 10 mL 0.25% bupivacaine	None
Santos O, Jun-19, Portugal <sup>16</sup>	Case report	Hip arthroplasty	One adult	PENG block with 20 mL 0.5% ropivacaine and 4 mg dexamethasone	Nerve catheter - additional 15 mL 0.5% ropivacaine intra-operatively+5 mL/hour 0.2% ropivacaine for 48 hours
<b>PENG block in combination with local anesthetic infiltration for analgesia</b>					
Sandri M, Mar-2020, Italy <sup>17</sup>	Case series	Hip arthroplasty	Ten patients	PENG block preoperatively with 40 mL 0.25% levobupivacaine and 4 mg dexamethasone	10 mL 1% mepivacaine at surgical incision site
Fusco P, Apr-19, Italy <sup>18</sup>	Case series	Hip arthroplasty	Four patients	PENG block preoperatively with 20 mL solution containing 0.375% levobupivacaine and 4 mg dexamethasone	None
<b>PENG block in combination with LFCN block for analgesia</b>					
Roy R, Jun-19, India <sup>9</sup>	Case series	Hip fracture surgery	Five later patients—age not stated	PENG block—local anesthetic solution not described	LFCN block—local anesthetic solution not described
Reza PC, Jan-20, Spain <sup>19</sup>	Case series	Hip arthroplasty, acetabular fracture surgery	Seven patients	PENG block with 20 mL 0.375% bupivacaine	LFCN block—5 mL 0.375% bupivacaine
Thallaj A, Oct/Dec-19, Saudi Arabi <sup>20</sup>	Case report	Hip arthroplasty	One adult	PENG block with 30 mL 0.25% bupivacaine	LFCN block with 5 mL 0.25% bupivacaine
<b>PENG block in combination with femoral nerve block for analgesia</b>					
Orozco S, Apr-19, Colombia <sup>21</sup>	Case series	Hip arthroscopy	Five adults	PENG block preoperatively with 20 mL of 0.75% bupivacaine and 1% lignocaine	FNB with 20 mL of 0.75% bupivacaine+1% lignocaine
<b>PENG block in combination with LFCN block and femoral nerve block for analgesia</b>					
Orozco S, Apr-19, Colombia <sup>22</sup>	Case report	Hip surgery—osteosynthetic material retrieval	One pediatric	PENG block with 10 mL 0.5% bupivacaine	FNB with 15 mL 1% lignocaine/0.75% levobupivacaine and LFCN block with 5 mL 1% lignocaine/0.75% levobupivacaine
<b>PENG block in combination with lumbar erector spinae block for analgesia</b>					
Ince I, Jan-20, Turkey <sup>23</sup>	Case report	Congenital hip dislocation surgery	One pediatric	PENG block with 8 mL 0.25% bupivacaine	Lumbar erector spinae plane block with 12 mL 0.25% bupivacaine
Ince I, Jan-20, Turkey <sup>24</sup>	Case series	Hip arthroplasty	Three adults	PENG block with 10 mL 0.5% bupivacaine and 10 mL 2% lignocaine	Lumbar erector spinae plane block with 30 mL 0.25% bupivacaine
<b>PENG block as a sole anesthetic technique for analgesia</b>					
Ueshima H, Sep-19, Japan <sup>25</sup>	Case report	Reduction of hip dislocation	Two adults	PENG block with 10 mL of 1% lignocaine	None

Continued

Table 1 Continued

First author, publication date, country (Reference)	Local anesthetic infiltration	Outcomes—analgesic efficacy	Outcomes—adverse effects	Comparison group
PENG block in isolation for analgesia				
Giron-Arango L, Nov-18, Canada <sup>5</sup>	NA	Reduction in NRS pain scores at rest (median reduction 7) and on movement at 30 min	None reported	Compared with patients pre-PENG block pain scores
Mistry T, Mar-19, India <sup>7</sup>	NA	All patients reported dynamic pain relief after 10–15 min without any motor weakness	None reported	None
Yu HC, May-19, Canada <sup>8</sup>	NA	Additional opioids required for postoperative analgesia in both patients	Description of 2 patients who experienced motor weakness post PENG block attributed to incorrect needle positioning	NA
Roy R, Jun-19, India <sup>9</sup>	NA	A few patients required rescue opioids for dermatomal pain	None reported	Authors describe that in their experience PENG block provides satisfactory reduction in pain for hip surgeries compared with other blocks available
Romero A, Jun-19, Costa Rica <sup>10</sup>	NA	Complete analgesia, no motor block	None reported	NA
Ueshemia H, Sep-19, Japan <sup>11</sup>	NA	Additional analgesics not required, uneventful perioperative course, no clear description of pain outcomes/analgesic medications	None reported	NA
Acharya, U. Mar-19, Nepal <sup>12</sup>	NA	Marked reduction in NRS pain scores when compared with pre-block, able to self-position for sitting spinal anesthesia in 9/10 cases with mild pain only on movement, able to sit without support post block	None reported	Compared with patients pre-PENG block NRS pain scores
Ahiskalioglu A, Nov-19, Turkey <sup>13</sup>	NA	VAS preprocedure 9 at rest, at 10 min post-PENG block 1 at rest, on movement 2	None reported	Compared with patients pre-PENG block pain scores
Bilal, Jan-20, Turkey <sup>14</sup>	NA	Maximum post-operative pain score during first 24 hours 3/10. No postoperative opioids required	None reported	NA
Aksu C, May-20, Turkey <sup>15</sup>	NA	Single-dose Ibuprofen 10 hours postoperatively, no additional analgesia required	None reported	NA
Santos O, Jun-19, Portugal <sup>16</sup>	NA	At 8 hours pain 2/10 at rest and 2/10 on movement. At 24 hours and 48 hours pain 0/10 at rest and 0/10 on movement with no further analgesia required	None reported	NA
PENG block in combination with local anesthetic infiltration for analgesia				
Sandri M, Mar-2020, Italy <sup>17</sup>	Yes	All 10 patients underwent surgery with 'light-moderate sedation', general anesthesia not required, maximal postoperative pain score reported 4/10, nil postoperative opioids required	None reported	NA
Fusco P, Apr-19, Italy <sup>18</sup>	Yes	Pain at rest on Numerical Rating Scale 'two controls', pain on movement 'four controls', patient reported lower perceived pain and 'very satisfied', no supplementary opioids/non-steroidal anti-inflammatory drugs	None reported	NA
PENG block in combination with LFCN block for analgesia				
Roy R, Jun-19, India <sup>9</sup>	NA	No rescue opioids required	None reported	NA
Reza PC, Jan-20, Spain <sup>19</sup>	NA	Pain outcomes not reported, only opioid consumption, 4 patients no opioids required postoperatively, 3 patients 6 mg or less intravenous morphine in first 24 hours	None reported	NA
Thallaj A, Oct/Dec-19, Saudi Arabi <sup>20</sup>	NA	Analgesia with paracetamol only postoperatively. 0–24 hours pain at rest 0/10, at 36 hours pain 2/10 at rest, at 48 hours pain 3/10 on movement	None reported	NA
PENG block in combination with femoral nerve block for analgesia				
Orozco S, Apr-19, Colombia <sup>21</sup>	NA	Highest VAS in the 24 hours postoperatively 3/10, after 48–72 hours all patients none or very low levels of pain requiring no opioid analgesia	None reported	NA
PENG block in combination with LFCN block and femoral nerve block for analgesia				
Orozco S, Apr-19, Colombia <sup>22</sup>	NA	72 hours follow-up maximum pain score 2/10, no additional analgesia required	None reported	NA
PENG block in combination with lumbar erector spinae block for analgesia				
Ince, I, Jan-20, Turkey <sup>23</sup>	NA	FLACC score maximum 1 for 24 hours follow-up. No postoperative opioids required	None reported	NA

Continued



Table 1 Continued

First author, publication date, country (Reference)	Local anesthetic infiltration	Outcomes—analgesic efficacy	Outcomes—adverse effects	Comparison group
Ince I, Jan-20, Turkey <sup>24</sup>	NA	Highest pain score in first 24 hours postoperatively 3/10, highest postoperative opioid consumption 8 mg intravenous morphine equivalent	None reported	NA
PENG block as a sole anesthetic technique				
Ueshima H, Sep-19, Japan <sup>25</sup>	NA	Successful reduction of hip dislocation in both patients without need for additional analgesia/ anesthesia	None reported	NA

FLACC, face legs, arms, cry, consolability pain scale; FNB, femoral nerve block; LFCN, lateral femoral cutaneous nerve; NA, not applicable; NRS, Numerical Rating Scale; PENG, pericapsular nerve group; VAS, Visual Analog Scale.

was transient.<sup>8</sup> To avoid traversing of nerves, leading to permanent damage, from happening, it has been suggested to identify the femoral nerve in the ‘scanning phase’ prior to performing PENG block.<sup>27</sup> The lateral femoral cutaneous nerve, on the contrary, has a smaller caliber, follows a less predictable path and is more difficult to identify on ultrasound. Finally, there is the potential that damage to the pelvic part of the ureter could occur if a more medial insertion site or a medial to lateral technique would be used.<sup>27</sup> Despite these concerns, however, none of these adverse events have been reported in the articles included in the current review.

Some limitations identified in the current review have to be addressed. It is possible that we may have missed PENG block articles published in languages other than English due to our review methods. English, however, is the most regular published language in medical literature. Due to the heterogeneity of the current PENG block reports in terms of indications, combinations with other nerve blocks, different local anesthesia solutions used, differences in follow-up and reporting of outcomes, it is not possible to draw firm conclusions on its efficacy based on the current data. Therefore, the current study was in the form of a scoping review to describe and map current evidence to identify areas for future research. Currently, there are no observational studies including large patient numbers or comparative trials of PENG blockage available and, as shown in the current review, literature is limited to case reports and case series. In view of this, randomized-controlled trials comparing PENG block to other nerve blocks, such as the fascia iliaca block, femoral nerve block, lumbar erector spinae block or a combination of blocks, are needed to provide evidence if PENG block is effective in providing analgesia for pain originating from the hip. We note that there are currently several registered randomized-controlled trials comparing PENG block to placebo blocks (NCT04231123) and to other nerve blocks for patients with pain derived from the hip (ACTRN12620000298910, ACTRN12619001410145, NCT04210700, NCT03783247, NCT04373577) with the aim to provide better evidence on the efficacy of PENG block for hip pain. Additionally, a large cohort study will be required to investigate its safety.

## Conclusions

This scoping review summarizes current available evidence on the use of PENG block as a regional analgesia and anesthesia technique for pain originating from the hip. Current literature suggests that PENG block is feasible and promising as a regional analgesia technique. Clinical trials and cohort series are required to determine its safety and efficacy.

**Twitter** Hidde Kroon @hiddekroon

**Acknowledgements** Nikki May, Clinical Librarian South Australian Health Library Service, Adelaide, South Australia, Australia.

**Contributors** CM was responsible for review design, search, reviewing results and manuscript preparation. BB was responsible for review design, search, reviewing results and manuscript editing. D-YL was responsible for review design and manuscript editing. RJ was responsible for manuscript editing. HK was responsible for review oversight and manuscript editing. All authors contributed to the manuscript and all authors approved submission.

**Funding** The authors have not declared a specific grant for this research from any funding agency in the public, commercial or not-for-profit sectors.

**Competing interests** None declared.

**Patient consent for publication** Not required.

**Provenance and peer review** Not commissioned; externally peer reviewed.

**Data availability statement** All data relevant to the study are included in the article or uploaded as supplementary information.

## ORCID iD

Craig Morrison <http://orcid.org/0000-0001-9200-2430>

## REFERENCES

- Guay J, Parker MJ, Griffiths R, *et al.* Peripheral nerve blocks for hip fractures. *Cochrane Database Syst Rev* 2017;5:CD001159.
- Myles PS, Myles DB, Galagher W, *et al.* Measuring acute postoperative pain using the visual analog scale: the minimal clinically important difference and patient acceptable symptom state. *Br J Anaesth* 2017;118:424–9.
- National Clinical Guideline Centre (NCGC) at the Royal College of Physicians. Chapter 7: Analgesia, paragraph 7.3. In: *The management of hip fracture in adults*. London, UK, 2019. <https://www.nice.org.uk/guidance/cg124/evidence/full-guideline-pdf-183081997>
- Short AJ, Barnett JGG, Gofeld M, *et al.* Anatomic study of innervation of the anterior hip capsule: implication for image-guided intervention. *Reg Anesth Pain Med* 2018;43:186–92.
- Giron-Arango L, Peng PWH, Chin KJ, *et al.* Pericapsular nerve group (PENG) block for hip fracture. *Reg Anesth Pain Med* 2018;43:859–63.
- Peters MDJ, Godfrey C, McInerney P, *et al.* Chapter 11: Scoping reviews (2020 version). In: *Joanna Briggs Institute Reviewer's Manual, JBI*, 2020. <https://reviewersmanual.joannabriggs.org/>
- Mistry T, Sonawane KB, Kuppasamy E. PENG block: points to ponder. *Reg Anesth Pain Med* 2019;44:423.2–4.
- HC Y, Moser JJ, Chu AY, *et al.* Inadvertent quadriceps weakness following the pericapsular nerve group (PENG) block. *Reg Anesth Pain Med* 2019;44:611–3.
- Roy R, Agarwal G, Pradhan C, *et al.* Total postoperative analgesia for hip surgeries, PENG block with LFCN block. *Reg Anesth Pain Med* 2019;44:684.1–684.
- Rocha Romero A, Carvajal Valdy G, Lemus AJ. Ultrasound-Guided pericapsular nerve group (PENG) hip joint phenol neurolysis for palliative pain. *J Can Anesth* 2019;66:1270–1.
- Ueshima H, Otake H. Clinical experiences of pericapsular nerve group (PENG) block for hip surgery. *J Clin Anesth* 2018;51:60–1.
- Acharya U, Lamsal R. Pericapsular nerve group block: an excellent option for analgesia for positional pain in hip fractures. *Case Rep Anesthesiol* 2020;2020:1830136
- Ahiskalioglu A, Aydin ME, Celik M, *et al.* Can high volume pericapsular nerve group (PENG) block act as a lumbar plexus block? *J Clin Anesth* 2020;61:109650.
- Bilal B, Öksüz G, Boran Ömer Faruk, Boran OF, *et al.* High volume pericapsular nerve group (PENG) block for acetabular fracture surgery: a new horizon for novel block. *J Clin Anesth* 2020;62:109702.

- 15 Aksu C, Cesur S, Kuş A, Kus A. Pericapsular nerve group (PENG) block for postoperative analgesia after open reduction of pediatric congenital dysplasia of the hip. *J Clin Anesth* 2020;61:109675.
- 16 Santos O, Pereira R, Cabral T, et al. Is continuous PENG block the new 3-in-1? *J Anesth Clin Res* 2019;10:898.
- 17 Sandri M, Blasi A, De Blasi RA. PENG block and LIA as a possible anesthesia technique for total hip arthroplasty. *J Anesth* 2020;34:472–5.
- 18 Fusco P, Di Carlo S, Paladini G, et al. Could the combination of PENG block and LIA be a useful analgesic strategy in the treatment of postoperative pain for hip replacement surgery? *Reg Anesth Pain Med* 2019;44:531.
- 19 Reza PC, Garcia PD, Vazquez MG, et al. Pericapsular nerve group block for hip surgery. *Minerva Anestesiol* 2020;86:463–5.
- 20 Thallaj A. Combined PENG and LFCN blocks for postoperative analgesia in hip surgery-A case report. *Saudi J Anaesth* 2019;13:381–3.
- 21 Orozco S, Muñoz D, Jaramillo S, et al. Pericapsular nerve group (PENG) block for perioperative pain control in hip arthroscopy. *J Clin Anesth* 2020;59:3–4.
- 22 Orozco S, Muñoz D, Jaramillo S, et al. Pediatric use of Pericapsular nerve group (PENG) block for hip surgical procedures. *J Clin Anesth* 2019;57:143–4.
- 23 Ince I, Kilicaslan A. Combination of lumbar erector spinae plane block (LESP) and Pericapsular nerve group (PENG) block in hip surgery. *J Clin Anesth* 2020;61:109672.
- 24 Ince I, Kilicaslan A, Kutlu E, et al. Combined pericapsular nerve block (PENG) and lumbar erector spinae plane (ESP) block for congenital hip dislocation surgery. *J Clin Anesth* 2020;61:109671.
- 25 Ueshima H, Otake H. Pericapsular nerve group (PENG) block is effective for dislocation of the hip joint. *J Clin Anesth* 2019;52:83.
- 26 Bartels K, Mayes LM, Dingmann C, et al. Opioid use and storage patterns by patients after hospital discharge following surgery. *PLoS One* 2016;11:e0147972.
- 27 Black ND, Chin KJ. Pericapsular nerve group (PENG) block: comments and practical considerations. *J Clin Anesth* 2019;56:143–4.

# Correction: *Analgesia and anesthesia using the pericapsular nerve group block in hip surgery and hip fracture: a scoping review*

Morrison C, Brown B, Lin D, *et al.* Analgesia and anesthesia using the pericapsular nerve group block in hip surgery and hip fracture: a scoping review. *Reg Anesth Pain Med* 2021;46:169–175. doi:10.1136/rapm-2020-101826

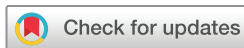The authors wish to direct the readers' attention to the retraction of two case reports cited in this review that been retracted due to academic misconduct.<sup>1</sup>

The first retracted article 'Clinical experiences of the pericapsular nerve group (PENG) block for hip surgery' was consistent with other articles described in the scoping review and thus the conclusion remains unchanged.<sup>2</sup>

The second retracted article 'Pericapsular nerve group (PENG) block is effective for dislocation of the hip joint' was the only article describing the PENG block as a sole anesthetic technique.<sup>3</sup> Thus on page three the paragraph subtitled 'Anesthesia outcomes' and on page four the tabled results subtitled 'PENG block as a sole anesthetic technique for analgesia' should be disregarded.

© Author(s) (or their employer(s)) 2022. No commercial re-use. See rights and permissions. Published by BMJ.

*Reg Anesth Pain Med* 2022;47:e1. doi:10.1136/rapm-2020-101826corr1



## REFERENCES

- 1 The Japanese Society of Anesthesiologists. Report of the investigation of research papers authored by Dr Hironobu Ueshima, 2021. Available: [https://anesth.or.jp/img/upload/ckeditor/files/2105\\_34\\_700\\_2.pdf](https://anesth.or.jp/img/upload/ckeditor/files/2105_34_700_2.pdf) [Accessed 02 Feb 2022].
- 2 Ueshima H, Otake H. Retracted: clinical experiences of pericapsular nerve group (PENG) block for hip surgery. *J Clin Anesth* 2018;51:60–1.
- 3 Ueshima H, Otake H. Retracted: Pericapsular nerve group (PENG) block is effective for dislocation of the hip joint. *J Clin Anesth* 2019;52:83.



## Appendix A

Database: Ovid MEDLINE(R) and Epub Ahead of Print, In-Process & Other Non-Indexed Citations and Daily <1946 to April 18, 2020>

Search Strategy:

- 
- 1 pericapsular nerve group.ti,ab,kf. [standalone term]
  - 2 Autonomic Nerve Block/
  - 3 nerve block\*.ti,ab,kf.
  - 4 plane block\*.ti,ab,kf.
  - 5 PENG.ti,ab,kf.
  - 6 or/2-5 [nerve block concept]
  - 7 hip/ and (exp Orthopedic Procedures/ or Surgical Procedures, Operative/)
  - 8 hip/su
  - 9 (hip\* adj5 (surg\* or operat\* or orthopedic\* or orthopaedic\* or fractur\* or arthroplast\* or arthroscop\* or relocation or dislocat\* or pain\* or joint\*).ti,ab,kf.
  - 10 ((femur\* or femor\*) adj3 (surg\* or fractur\* or arthroplast\* or arthroscop\* or relocation or dislocat\*).ti,ab,kf.
  - 11 ((trochant\* or petrochant\* or intertrochant\* or subtrochant\*) adj3 (surg\* or fractur\* or arthroplast\* or arthroscop\* or relocation or dislocat\*).ti,ab,kf.
  - 12 ((intracapsular\* or extracapsular\*) adj3 (surg\* or fractur\* or arthroplast\* or arthroscop\* or relocation or dislocat\*).ti,ab,kf.
  - 13 lower extremit\*.kf.
  - 14 (thigh adj4 surg\*).ti,ab,kf.
  - 15 or/7-14 [hip surgeries concept]
  - 16 and/6,15 [joining nerve block and hips]
  - 17 or/1,5,16 [adding in standalone term]
  - 18 limit 16 to yr="2018-Current"