

# Preoperative pericapsular nerve group (PENG) block for total hip arthroplasty: a randomized, placebo-controlled trial

Jun Zheng,<sup>1</sup> Danyang Pan,<sup>1</sup> Bin Zheng,<sup>1</sup> Xiangcai Ruan <sup>2</sup>

► Additional supplemental material is published online only. To view, please visit the journal online (<http://dx.doi.org/10.1136/rapm-2021-103228>).

<sup>1</sup>The Second Affiliated Hospital, School of Medicine, South China University of Technology, Guangzhou, China

<sup>2</sup>Department of Anesthesiology and Pain Medicine, Sun Yat-sen University, Guangzhou, China

## Correspondence to

Dr Xiangcai Ruan, Department of Anesthesiology and Pain Medicine, Sun Yat-sen University, Guangzhou 510275, China; [ruanxc@mail.sysu.edu.cn](mailto:ruanxc@mail.sysu.edu.cn)

Received 5 October 2021

Accepted 20 November 2021

## ABSTRACT

**Background** We hypothesized that the addition of a preoperative pericapsular nerve group (PENG) block to intra-articular local anesthetic injection would improve analgesia after total hip arthroplasty.

**Method** In this double-blinded trial, 71 patients scheduled for primary total hip arthroplasty were randomized to receive preoperative PENG block with 20 mL 0.5% ropivacaine (PENG group) or 20 mL saline (placebo group). All the patients received an intra-articular injection of 20 mL 0.5% ropivacaine by surgeon after the completion of the procedure. The primary outcome was the highest pain score reported in the recovery room. The secondary outcomes included quadriceps strength, pain scores, opioid use, and opioid-related side effects up to 48 hours after surgery.

**Results** Seventy patients were included in the final analysis. The highest visual analog scale in the recovery room showed significant intergroup difference (placebo:  $5.2 \pm 3.1$  vs PENG:  $3.3 \pm 2.7$ ,  $p < 0.01$ ) but the difference did not persist after discharge from the recovery room. The two groups' postoperative pain scores at rest were similar. A lower intraoperative morphine equivalent dose and lower postoperative vomiting were found in the PENG group. There were no differences in the other outcomes.

**Conclusion** The addition of a preoperative PENG block to intra-articular injections of local anesthetic provides a limited benefit to postoperative analgesia in the recovery room with no discernible benefits thereafter.

**Trial registration number** NCT04480320.

## INTRODUCTION

Total hip arthroplasty (THA), a frequently performed major surgery, is often associated with moderate to severe postoperative pain, particularly when performed without multimodal analgesia. Significant pain, if inadequately controlled, can impair early rehabilitation and functional recovery and can reduce patient satisfaction after surgery.<sup>1–3</sup> Combinations of systemic analgesics, intra-articular injection, and neuraxial and peripheral nerve blocks should be considered as the integral components of the perioperative pain management plan. Among these, intra-articular local anesthetic injections have been shown to play a potential role in providing analgesia after hip arthroplasty.<sup>4–6</sup> Several peripheral nerve blocks, including fascia iliaca block, femoral block, and some interfascial plane blocks such as quadratus lumborum block, have also been suggested to decrease postoperative pain

and opioid use.<sup>7–10</sup> However, femoral nerve block may induce weakness of the quadriceps muscles<sup>11</sup> and it is difficult to perform lumbar plexus or quadratus lumborum block due to their depth and mixed results regarding analgesic efficacy for the THA.<sup>11–13</sup> High-volume suprainguinal fascia iliaca block and traditional fascia iliaca block have also been reported to be associated with a significant incidence of muscle weakness and to predispose the patient to fall.<sup>8,14</sup>

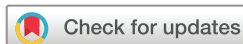Pericapsular nerve group (PENG) block for the management of acute pain after hip fracture has attracted significant interest of late due to its potential motor-sparing benefits,<sup>15,16</sup> which are desirable for early ambulation and functional recovery after surgery. It is even speculated that PENG block can provide analgesia after THA while preserving the motor function.<sup>16–18</sup> However, the evidence to support the use of PENG block is lacking in the current literature<sup>19</sup> and the technique is not mentioned in the recent postoperative pain management (procedure-specific postoperative pain management) guideline for THA.<sup>20</sup> The current study was therefore conducted to evaluate the clinical efficacy of adding PENG block to intra-articular local anesthetic injection in patients undergoing primary elective THA through a randomized, placebo-controlled trial.

We hypothesized that the addition of PENG block to intra-articular local anesthetic injection would reduce the highest pain scores reported in the recovery room. Our secondary outcomes were quadriceps strength, pain scores, opioid use, and opioid-related side effects up to 48 hours after surgery.

## Recruitment and randomization

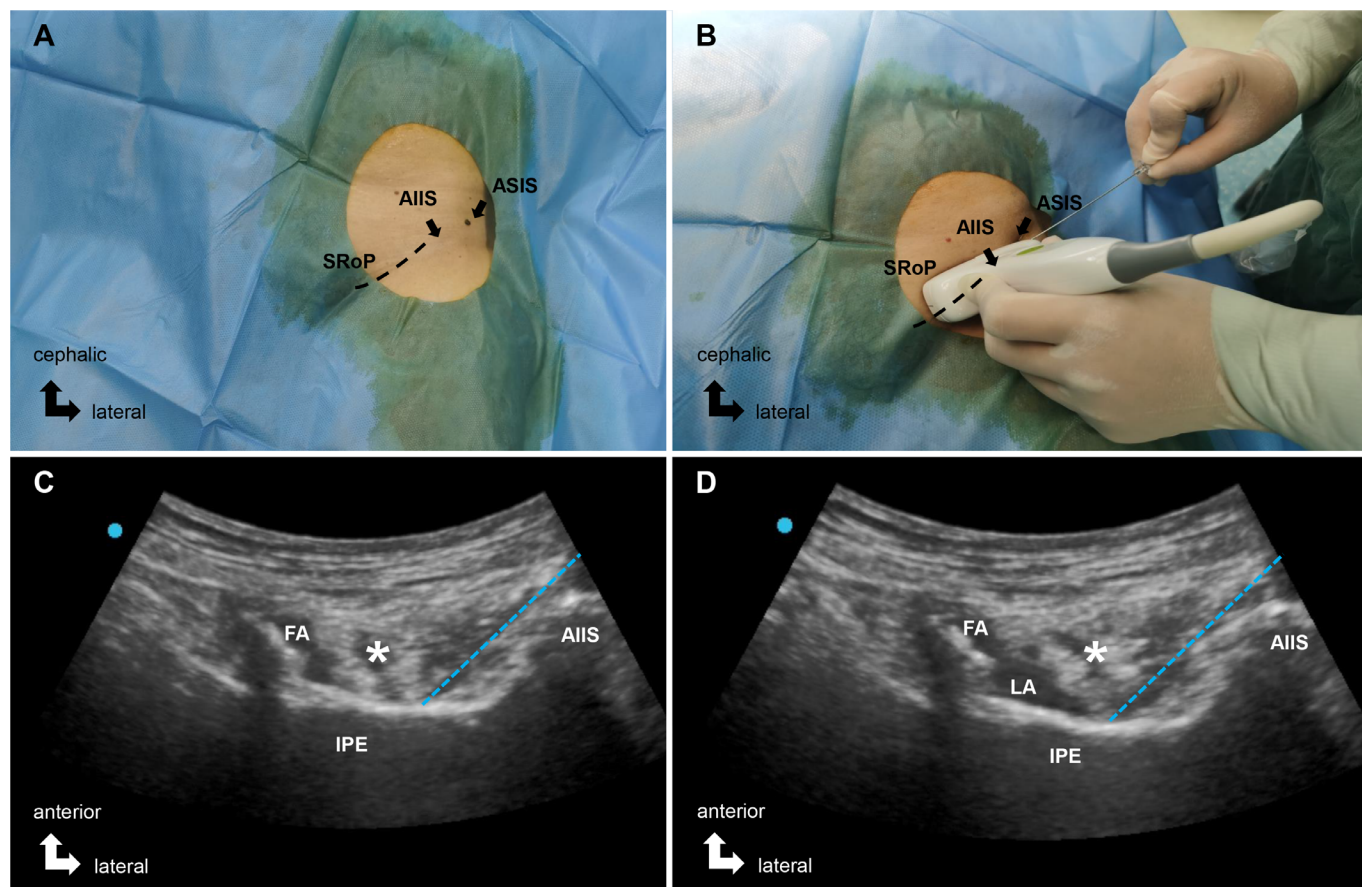
This single-center study was registered at ClinicalTrials.gov (principal investigator: XR, date of registration: 21 July 2020). It was conducted in accordance with the Consolidated Standards of Reporting Trials statement and Good Clinical Practice guidelines. Unblinding of the investigators performing the analysis was done after the completion of the patient enrollment and data collection. The protocol is available by request from the corresponding author.

All patients aged 18–70 years who underwent elective primary one-sided THA within the period from 10 September 2020 to 12 May 2021 were eligible to participate in the study. The exclusion criteria included the contraindications to peripheral



© American Society of Regional Anesthesia & Pain Medicine 2021. No commercial re-use. See rights and permissions. Published by BMJ.

**To cite:** Zheng J, Pan D, Zheng B, et al. *Reg Anesth Pain Med* Epub ahead of print: [please include Day Month Year]. doi:10.1136/rapm-2021-103228



**Figure 1** Images of ultrasound-guided pericapsular nerve group (PENG) block routinely used in current study. (A) Right hip in supine position. (B) Orientation of the ultrasound probe. (C) The needle tip was positioned between the psoas tendon and the pubic ramus using an in-plan approach. (D) The fact that the psoas tendon is slightly pushed upward is a reliable sign of adequate liquid spread. AIIS, anterior inferior iliac spine; ASIS, anterior superior iliac spine; FA, femoral artery; IPE, iliopubic eminence; LA, local anesthetic; SRoP, superior ramus of pubis.

nerve block (eg, allergy to lidocaine or ropivacaine, coagulopathy, infection in the injection site), pre-existing neurological impairment in any side of the lower limb, long-term use of opioids, decline of cognitive state, and inability to communicate. After giving their written consent to participate in the study, the subjects were randomly allocated to either the placebo group or the PENG group with an allocation ratio of 1:1 using an online randomization generator (<https://www.sealedenvelope.com>). The group designation data were sealed in sequentially numbered opaque envelopes, which were opened on the day of surgery by a study investigator who was then unblinded. The data collection was performed by blinded study investigators.

### Ultrasound-guided block procedures

The patients were subjected to standard monitoring and received nasal cannula oxygen (2 L/min). Midazolam (1–2 mg) was administered intravenously for light sedation.

Under sterile conditions, a low-frequency curvilinear probe of ultrasound (SonoSite S-Nerve Machine, Fujifilm) was initially placed in a transverse plane over the anterior inferior iliac spine, and was then rotated parallel to the pubic ramus to obtain a short-axis view of the iliopsoas muscle and tendon lying on the ramus pubic adjacent to the iliopubic eminence. After skin infiltration with 1–3 mL 1% lidocaine, a 23 G, 70 mm insulated block needle was inserted in-plane in a lateral-to-medial direction to place the tip in the musculofascial plane between the psoas tendon and the pubic ramus (figure 1A–D, online supplemental

video 1).<sup>15</sup> For the patients in the PENG block group, a total of 20 mL 0.5% ropivacaine (AstraZeneca, Sodertalje, Sweden) was injected slowly in 5 mL increments with intermittent aspiration and under constant ultrasound surveillance for adequate fluid spread. For the patients in the placebo group, 20 mL 0.9% saline was injected through the same process described above. The study drugs were prepared by the unblinded investigator while the block procedure was performed by an investigator blinded to the patients' study group designations.

Thirty minutes after the block completion, the patients' pain and quadriceps strength levels were repeatedly measured by the same investigator. Subsequently, this investigator assessed the potential extensive block by testing for loss of cold sensation on the front, lateral, and medial thigh and the medial lower leg, which were innervated by the femoral nerve, lateral femoral cutaneous nerve, obturator and femoral nerve, and saphenous nerve, respectively. The test was conducted with two cotton pads with ethanol, which were placed on the corresponding positions on both lower limbs at the same time. The patients were asked if there was a decreased cold sensation on the surgical side of the lower limb. All cold sensation decrease events were marked as 'positive' while the contrasting outcomes were marked as 'negative'.

### Intraoperative procedure

Subsequently, standardized endotracheal general anesthesia was induced with propofol (2–2.5 mg/kg), sufentanil (0.5–0.7 µg/kg),

and *cis*-atracurium (0.16–0.2 mg/kg), and was maintained with propofol and sevoflurane. Remifentanyl (0.05–2 µg/kg/min) was given intraoperatively as needed at the discretion of the anesthesiologist, who was blinded to the allocation result.

THA procedures using a posterolateral approach were performed by three teams of orthopedic surgeons with more than 20 years' experience. The surgeons were asked to perform intra-articular injection of 20 mL 0.5% ropivacaine at the end of each procedure for basic pain relief. The needle placement was under the surgeons' direct visualization. All the patients received 5 mg intravenous tropisetron (Harbin Medisan Pharmaceutical, Harbin, China) at the end of the surgery.

### Postoperative procedure

After surgery, the patients were transferred to the post-anesthesia care unit (PACU) for extubation and full recovery before being transferred to the surgical ward. Any patient who met the transfer requirements should have also met the requirement of visual analog scale (VAS) pain at rest of less than 4; if not, rescue opioid IV 2.5 mcg sufentanil increments would be given to the patient until basic pain relief was achieved. The patients were treated with oral ketorolac and acetaminophen for background pain control after they were sent back to the ward, with intravenous tramadol/butorphanol/meperidine allowed in the case of an acute pain attack. The specific type of medication and dosage were chosen by the blinded treating physicians with circumspection to reflect daily practice.

### Outcomes

The primary outcome was the highest VAS pain score reported during patients' PACU stay. The secondary endpoints were the quadriceps strength, pain scores, opioid use, and opioid-related side effects 48 hours after surgery.

The patients' baseline pain scores and quadriceps strength levels were determined 1 day before the surgery. The patients were asked to mark the point on a VAS that best represented the level of pain intensity they were experiencing (0, no pain; 10, worst imaginable pain) at rest, and to mark the point on another VAS that best represented the highest level of pain intensity they were experiencing while moving. The quadriceps strength was assessed by measuring the average force produced by three quadriceps contractions with a handheld dynamometer (HANDPI, Zhejiang, China). To obtain knee extension strength measurements of the quadriceps femoris group, the patients were made to assume a supine position, with the knee flexed naturally (60°–90°). The force plate of the handheld dynamometer was placed on the tibia 2 cm proximal to the center of the medial malleolus. The investigator blinded to the group allocation then stabilized the thigh proximally while stably holding the dynamometer. The patients were encouraged to flex their knee and to push it maximally against the force plate through the standardized line 'Keep pushing as hard as you can; push, push, then relax' in three rounds, with the average value from the three force peaks recorded.<sup>21</sup> The cold sensation and quadriceps strength tests were repeated before the patients' PACU discharge. The same investigator then assessed the pain scores, quadriceps strength levels, opioid use, opioid-related side effects, and fall 6, 24, and 48 hours thereafter. Any fall incident was recorded. The overall satisfaction was assessed via VAS, by making each patient mark any point thereon representing a score from 0 (not satisfied) to 10 (most satisfied) 48 hours after the patient's PACU discharge.

### Sample size calculation

We used G\*Power V.3.1.9.4 for sample size calculation. On the basis of our preliminary study, we expected that the highest VAS score of the sham block group recorded in the PACU would be  $5.2 \pm 2.4$ , and that the PENG block group would do 33% better, with a  $3.5 \pm 2.4$  value. Through a two-sided test with  $\alpha = 0.05$  and  $\beta = 0.2$ , we determined that the required sample size was approximately 64. To allow a 10% protocol violation and dropout rate, we planned to recruit a total of 71 patients.

### Statistical analysis

The obtained data were analyzed using SPSS V.25 (IBM SPSS Statistics, 2018). Continuous data with normal distribution were presented as mean (95% CIs) or percentage (%). Baseline comparisons between the groups were made using Student's t-test or the Mann-Whitney U test, on the basis of the viability of the normality assumption for continuous variables. The VAS pain scores and quadriceps strength levels at different time points were analyzed using a repeated measures analysis of variance model with one between-subject factor (treatment group) and one within-subject factor (time) and their interaction, followed by Bonferroni post hoc tests for pairwise comparisons. The incidences of nausea, vomiting, muscle weakness, and sensory changes at each time were compared using  $\chi^2$  or Fisher's exact tests as appropriate. Statistical significance was set at  $p < 0.05$  for each outcome on the basis of a one-tailed probability.

### RESULTS

A total of 98 patients were screened for eligibility to participate in this study, and 71 of them were eventually enrolled in the study. One group-allocated patient was removed from the study before receiving the study intervention due to surgery change; the remaining 70 patients completed the study and were included in the final analysis (figure 2).

The demographic and baseline characteristics of the 36 patients in the placebo group and the 34 patients in the PENG group were comparable. Their surgery durations and lengths of PACU stay were also comparable. No intraoperative complications were noted in the patients (table 1).

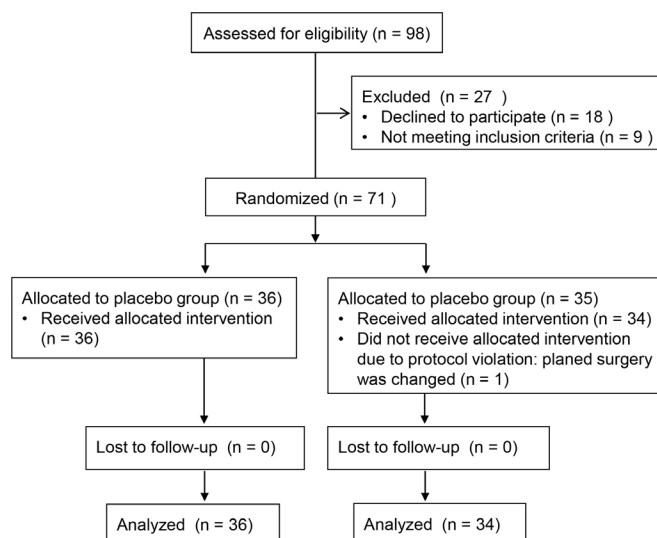


Figure 2 Patient flow diagram.



**Table 1** Patient characteristics presented as mean (95% CI) or absolute number as appropriate

|   | Placebo group<br>(n=36) | PENG group<br>(n=34) |
|---|-------------------------|----------------------|
| Sex (male/female)                             | 15/21                   | 12/22                |
| Age (year)                                    | 64 (59 to 68)           | 63 (57 to 69)        |
| Weight (kg)                                   | 58 (55 to 62)           | 56 (51 to 61)        |
| Height (cm)                                   | 159 (156 to 162)        | 159 (156 to 161)     |
| BMI (kg/m <sup>2</sup> )                      | 23.6 (22.5 to 24.6)     | 23.3 (21.7 to 24.9)  |
| ASA physical status (I/II/III)                | 1/28/7                  | 3/27/4               |
| Surgical side (left/right)                    | 15/21                   | 16/18                |
| Preoperative diagnosis (fracture/no fracture) | 6/30                    | 8/26                 |
| Duration of surgery (min)                     | 106 (94 to 118)         | 113 (97 to 129)      |
| Duration of PACU stay (min)                   | 43 (39 to 48 )          | 39 (34 to 45)        |

ASA, American Society of Anesthesiologists; BMI, body mass index; PACU, postanesthesia care unit; PENG, pericapsular nerve group.

### Primary outcome

The two groups' highest pain scores in the PACU were significantly different from each other, with a  $-1.9$  difference (95% CI  $-3.3$  to  $0.5$ ). After the patients' PACU discharge, there were no differences between the two groups' highest pain scores (table 2).

### Secondary outcomes

No differences in the two groups' pain scores at rest during the study period were recorded (table 2). Although the intraoperative opioid consumption including the opioid consumption at induction of anesthesia was lower in the PENG group than in the placebo group, the two groups had similar levels of rescue opioid use during their PACU stay and 48 hours after their PACU discharge (table 3).

There were no significant between-group differences in quadriceps strength levels on either the operated side or the non-operated side during the study period (figure 3), and in the incidence of decreased skin sensation in the skin distribution of the related nerves 30 min after the study intervention and on PACU discharge (table 4). The incidence of nausea was comparable between the groups, but the incidence of vomiting was reduced in the PENG group (4 (12%) vs 12 (33%);  $p=0.03$ ).

No postoperative fall was recorded. One patient from the placebo group, however, was diagnosed with delirium 6 hours after PACU discharge and did not complete the follow-up

assessment. The overall patient satisfaction was high in both groups, with no difference found between the groups (table 4).

### DISCUSSION

In our randomized placebo-controlled trial, the addition of PENG block to a multimodal regimen including intra-articular injections of local anesthetic conferred limited benefits to early postoperative analgesia in patients undergoing primary THA. Unfortunately, these benefits did not persist after discharge from the recovery room and no evidence of benefit in terms of secondary analgesic outcomes, including the postoperative pain scores and opioid consumption, was found.

The limited analgesic benefits in our study contrast what is indicated in the existing literature that addresses this technique in THA patients. Previous observational studies have shown that PENG block alone<sup>22 23</sup> or in combination with regional analgesia, including periarticular infiltration techniques<sup>24</sup> and spinal anesthesia,<sup>25</sup> is associated with decreased postoperative pain scores and opioid use up to 24 hours after surgery. A recent study published online in July 2021, while we were preparing this article, compared preoperative PENG block with no treatment in conscious patients and reported that the decreases in pain scores reached statistical significance at all the time points and up to 48 hours after surgery.<sup>18</sup> However, the subjects in the said study were not blinded to the invasive pain intervention, and the placebo effect would have made the evaluation very difficult. The discrepancy could also have been related to the different anesthesia techniques used (spinal vs general anesthesia), to the levels of postoperative pain intensity (highest VAS  $>5$  vs highest VAS  $<5$ ), and to the basic analgesia techniques used (local infiltration analgesia vs intra-articular injection of local anesthetic).

We added monitoring of the supine quadriceps strength to indirectly assess the functional recovery after surgery. No difference was seen between the groups on PACU discharge or 6, 24, or 48 hours thereafter, demonstrating the motor-sparing characteristics of PENG block. Furthermore, no postoperative falls were reported in either group. These should not be surprising as similar trends have been observed in patients with hip fracture, illustrating the quadriceps strength sparing and faster knee function recovery after PENG block.<sup>15 16</sup> Quadriceps strength sparing is imperative for peripheral nerve block in the lower extremity because quadriceps weakness hinders early ambulation/rehabilitation and increases the risk of postoperative falls.<sup>26–28</sup>

**Table 2** Pain-related outcomes presented as mean $\pm$ SD or risk difference (95% CI) between the study groups

|                                  | Placebo group    | PENG block group | Mean difference (95% CI)    | P value |
|----------------------------------|------------------|------------------|-----------------------------|---------|
| Highest VAS score                |                  |                  |                             |         |
| Preoperative                     | 5.5 $\pm$ 2.3    | 5.1 $\pm$ 2.1    | $-0.4$ ( $-0.7$ to $1.5$ )  | 0.46    |
| During PACU stay                 | 5.2 $\pm$ 3.1    | 3.3 $\pm$ 2.7    | $-1.9$ ( $0.5$ to $3.3$ )   | $<0.01$ |
| 0–6 hours after PACU discharge   | 4.5 (3.5 to 5.4) | 4.6 (3.7 to 5.4) | $0.1$ ( $-1.3$ to $1.1$ )   | 0.89    |
| 6–24 hours after PACU discharge  | 4.0 (3.2 to 4.8) | 3.7 (3.0 to 4.4) | $-0.3$ ( $-0.7$ to $1.3$ )  | 0.58    |
| 24–48 hours after PACU discharge | 3.3 (2.5 to 4.1) | 3.1 (2.3 to 3.8) | $-0.2$ ( $-0.9$ to $1.3$ )  | 0.68    |
| VAS score at rest                |                  |                  |                             |         |
| Preoperative                     | 1.5 $\pm$ 2.2    | 1.1 $\pm$ 1.7    | $-0.4$ ( $-0.5$ to $1.3$ )  | 0.40    |
| On PACU discharge                | 2.5 $\pm$ 2.1    | 1.8 $\pm$ 2.3    | $-0.7$ ( $-0.4$ to $1.8$ )  | 0.18    |
| 6 hours after PACU discharge     | 2.3 $\pm$ 2.2    | 1.8 $\pm$ 2.5    | $-0.5$ ( $-0.6$ to $1.6$ )  | 0.37    |
| 24 hours after PACU discharge    | 1.4 $\pm$ 1.3    | 0.9 $\pm$ 1.4    | $-0.5$ ( $-0.1$ to $1.1$ )  | 0.12    |
| 48 hours after PACU discharge    | 1.1 $\pm$ 1.4    | 0.6 $\pm$ 1.0    | $-0.6$ ( $-0.02$ to $1.1$ ) | 0.06    |

\*The mean difference is presented as mean (PENG group) – mean (placebo group) and 95% CI. PACU, postanesthesia care unit; PENG, pericapsular nerve group; VAS, visual analog scale.

**Table 3** Opioid consumption-related outcomes and opioid-related side effects presented as mean±SD, absolute number (proportions) as appropriate, and risk difference (95% CI) between the groups

|  | Placebo group | PENG group | Mean difference (95% CI) | P value |
|--|---------------|------------|--------------------------|---------|
| Intraoperative MED consumption (mg)                | 83.0±29.5     | 69.1±25.7  | -13.8 (0.6 to 27.1)      | 0.04    |
| MED consumption during PACU discharge              | 3.3±8.8       | 1.3±3.5    | -2.0 (-1.2 to 5.3)       | 0.21    |
| MED consumption 48 hours after PACU discharge (mg) | 14.5±25.0     | 18.0±29.2  | 3.5 (-16.4 to 9.4)       | 0.59    |
| Postoperative nausea and vomiting                  |               |            |                          |         |
| Nausea   | 5 (13.9%)     | 6 (17.6%)  | 3.8% (-15.6% to 23.3%)   | 0.67    |
| Vomiting   | 12 (33.3%)    | 4 (11.8%)  | -21.6% (-0.3% to 41.0%)  | 0.03    |

The mean difference is presented as mean (PENG group) – mean (placebo group) and 95% CI.

Intravenous MED (mg) equation: (sufentanil [mcg]) + 11 (remifentanyl [mcg] × 0.1) + (tramadol [mg] × 0.1) + (butorphanol [mg] × 5) + 12 (meperidine [mg] × 0.1).

MED, morphine equivalent doses; PACU, postanesthesia care unit; PENG, pericapsular nerve group.

The differential analgesic effects of the addition of motor-sparing block with intra-articular injection of local anesthetic seemed to have been quickly resolved because no significant difference in either the pain scores or opioid use was found between the groups after discharge from the recovery room. The potential beneficial motor-sparing and analgesic effects of PENG block are thus negated by the short-duration single-shot technique. Recently, Singh<sup>29</sup> conducted an observational pilot study on how to maximize the advantage of PENG block and reported a successful case of prolonging the duration of analgesia achieved by PENG block for 3 days after THA through the use of a catheter. The clinical efficacy of continuous or multi-dosing PENG block warrants further investigation.

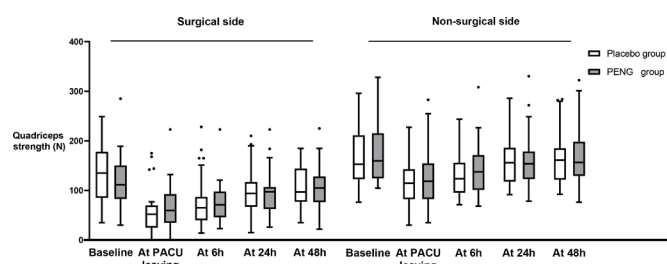
Our study had several limitations. First, it used an intra-articular injection of local anesthetic for basic postoperative analgesia in THA patients. Intra-articular injection of local anesthetic is frequently used for pain control after major joint arthroplasty in our institution due to its operation convenience and practicality.<sup>5</sup> However, the target of PENG block is the anterior capsule while intra-articular injection also targets the hip capsule pain after the joint replaced. This methodology with intra-articular injection in both groups may limit the usefulness of PENG block and affect the external validity to most institutions which do not practice intra-articular injection. The use of intra-articular injection of local anesthetic may also contribute to the overall low pain scores throughout the postoperative period. Most of the patients in the postoperative period rated the highest VAS <5, and for resting pain score, it is much less than 3 in most period. This is consistent with a recent published report. Aliste *et al*<sup>17</sup> compared the PENG block with suprainguinal fascia iliac block and reported that the postoperative pain scores were low and no differences in analgesia were detected between the groups. One can argue that Aliste *et al*'s study was not built to have sample size to detect the difference in analgesia; however, a low pain

score prevalent in the study pain population certainly makes the detection of intergroup difference more difficult.

Another limitation of our study, like other studies on THA patients,<sup>8</sup> was the utilization of general anesthesia. We designed the general anesthesia protocol to prevent the residual effect of neuraxial anesthesia, which may conceal the state of pain and quadriceps strength at the early postoperative period. However, the intraoperative use of short-acting opioid analgesics such as remifentanyl has been associated with acute opioid tolerance and/or opioid-induced hyperalgesia. The placebo group did not benefit from the pre-emptive PENG block and thus required higher intraoperative opioid consumption in the form of short-acting opioids (sufentanil and remifentanyl). The higher intraoperative opioid use may have caused acute hyperalgesia and may have influenced the immediate pain scores after surgery. Therefore, our findings are specific to patients receiving general anesthesia as it is possible that a different anesthetic technique, such as spinal anesthesia, will produce different results in the immediate postoperative period.

Intraoperative anesthetic and opioid administration was at the discretion of the attending anesthesiologist, which might have had a confounding effect on the primary outcome of pain scores in the recovery room. Also, postoperative analgesics are not standardized, with too many opioid and opiate options, which makes the comparison of the two groups in such regard difficult. A simple regimen based on patient-controlled analgesia or even a single oral opioid administration could have allowed a better comparison of the two groups.

In conclusion, our trial demonstrated a minor benefit of the addition of a preoperative PENG block to intra-articular local

**Figure 3** Quadriceps strength-related outcomes, presented as mean±SD. The unit of strength is newton. Repeated measures analysis of variance detected no statistically significant effects between the groups. PACU, postanesthesia care unit; PENG, pericapsular nerve group.**Table 4** Skin sensation test results presented as absolute number (proportion) or mean±SD as appropriate, and overall satisfaction measured using VAS (0–10)

|   | Placebo group | PENG group | P value |
|---|---------------|------------|---------|
| Skin cold sensation decreased 30 min after intervention |               |            |         |
| Lateral thigh   | 8 (22.2%)     | 10 (29.4%) | 0.49    |
| Front thigh   | 16 (44.4%)    | 13 (38.2%) | 0.60    |
| Medial thigh  | 9 (25.0%)     | 10 (25.4%) | 0.68    |
| Medial calf   | 4 (11.1%)     | 9 (26.5%)  | 0.10    |
| Skin cold sensation decreased on PACU discharge         |               |            |         |
| Lateral thigh   | 3 (8.3%)      | 6 (17.6%)  | 0.42    |
| Front thigh   | 8 (22.2%)     | 7 (20.6%)  | 0.87    |
| Medial thigh  | 4 (11.1%)     | 9 (26.5%)  | 0.10    |
| Medial calf   | 3 (8.3%)      | 6 (17.6%)  | 0.42    |
| Overall satisfaction                                    | 9±1           | 10±1       | 0.08    |

PACU, postanesthesia care unit; PENG, pericapsular nerve group; VAS, visual analog scale.

anesthetic injection in reducing early postoperative pain in the recovery room. There were no longer lasting effects either in terms of pain scores or opioid consumption after discharge from the recovery room, undermining the utility of this technique for patients undergoing primary THA.

**Contributors** JZ, DP, BZ, and XR participated in and designed all of the experiments. JZ and DP helped study conduct and data collection. JZ, BZ, and XR analyzed the data and wrote the manuscript. XR supervised the experiments and is the guarantor of the study. The authors read and approved the final manuscript.

**Funding** The authors have not declared a specific grant for this research from any funding agency in the public, commercial or not-for-profit sectors.

**Competing interests** None declared.

**Patient consent for publication** Not required.

**Ethics approval** This study was approved by the Institutional Ethics Committee (K-2020-085-01) of The Second Affiliated Hospital, School of Medicine, South China University of Technology, Guangzhou, People's Republic of China.

**Provenance and peer review** Not commissioned; externally peer reviewed.

**Data availability statement** Data are available upon reasonable request. Not applicable.

#### ORCID iD

Xiangcai Ruan <http://orcid.org/0000-0001-6112-7994>

#### REFERENCES

- Bober K, Kadado A, Charters M, *et al.* Pain control after total hip arthroplasty: a randomized controlled trial determining efficacy of fascia iliaca compartment blocks in the immediate postoperative period. *J Arthroplasty* 2020;35:S241–5.
- Højer Karlsen AP, Geisler A, Petersen PL, *et al.* Postoperative pain treatment after total hip arthroplasty: a systematic review. *Pain* 2015;156:8–30.
- Zhao J, Davis SP. An integrative review of multimodal pain management on patient recovery after total hip and knee arthroplasty. *Int J Nurs Stud* 2019;98:94–106.
- Andersen KV, Pfeiffer-Jensen M, Haraldsted V, *et al.* Reduced hospital stay and narcotic consumption, and improved mobilization with local and intraarticular infiltration after hip arthroplasty: a randomized clinical trial of an intraarticular technique versus epidural infusion in 80 patients. *Acta Orthop* 2007;78:180–6.
- Chen DW, Hu C-C, Chang Y-H, *et al.* Intra-articular bupivacaine reduces postoperative pain and meperidine use after total hip arthroplasty: a randomized, double-blind study. *J Arthroplasty* 2014;29:2457–61.
- Cui Y, Yang T, Zeng C, *et al.* Intra-Articular bupivacaine after joint arthroplasty: a systematic review and meta-analysis of randomised placebo-controlled studies. *BMJ Open* 2016;6:e011325.
- Desmet M, Vermeylen K, Van Herreweghe I, *et al.* A longitudinal Supra-Inguinal fascia Iliaca compartment block reduces morphine consumption after total hip arthroplasty. *Reg Anesth Pain Med* 2017;42:327–33.
- Gasanova I, Alexander JC, Estrera K, *et al.* Ultrasound-Guided suprainguinal fascia iliaca compartment block versus periarticular infiltration for pain management after total hip arthroplasty: a randomized controlled trial. *Reg Anesth Pain Med* 2019;44:206–11.
- Kuchálik J, Magnuson A, Lundin A, *et al.* Local infiltration analgesia or femoral nerve block for postoperative pain management in patients undergoing total hip arthroplasty. A randomized, double-blind study. *Scand J Pain* 2017;16:223–30.
- Nielsen ND. Peripheral nerve blocks for analgesia after elective total hip arthroplasty. *Acta Anaesthesiol Scand* 2020;64:829–30.
- Kolaczko JG, Knapik DM, Salata MJ. Peri-operative pain management in hip arthroscopy: a systematic review of the literature. *J Hip Preserv Surg* 2019;6:353–63.
- Brixel SM, Biboulet P, Swisser F, *et al.* Posterior quadratus lumborum block in total hip arthroplasty: a randomized controlled trial. *Anesthesiology* 2021;134:722–33.
- Kukreja P, MacBeth L, Sturdivant A, *et al.* Anterior quadratus lumborum block analgesia for total hip arthroplasty: a randomized, controlled study. *Reg Anesth Pain Med* 2019;44:rapm-2019-100804–9.
- Behrends M, Yap EN, Zhang AL, *et al.* Preoperative fascia Iliaca block does not improve analgesia after arthroscopic hip surgery, but causes quadriceps muscles weakness: a randomized, double-blind trial. *Anesthesiology* 2018;129:536–43.
- Girón-Arango L, Peng PWH, Chin KJ, *et al.* Pericapsular nerve group (PENG) block for hip fracture. *Reg Anesth Pain Med* 2018;43:1–63.
- Lin D-Y, Morrison C, Brown B, *et al.* Pericapsular nerve group (PENG) block provides improved short-term analgesia compared with the femoral nerve block in hip fracture surgery: a single-center double-blinded randomized comparative trial. *Reg Anesth Pain Med* 2021;46:398–403.
- Aliste J, Laya S, Bravo D, *et al.* Randomized comparison between pericapsular nerve group (PENG) block and suprainguinal fascia iliaca block for total hip arthroplasty. *Reg Anesth Pain Med* 2021;46:874–8.
- Pascarella G, Costa F, Del Buono R, *et al.* Impact of the pericapsular nerve group (PENG) block on postoperative analgesia and functional recovery following total hip arthroplasty: a randomised, observer-masked, controlled trial. *Anaesthesia* 2021;76:1492–8.
- Morrison C, Brown B, Lin D-Y, *et al.* Analgesia and anesthesia using the pericapsular nerve group block in hip surgery and hip fracture: a scoping review. *Reg Anesth Pain Med* 2021;46:169–75.
- Anger M, Valovska T, Beloeil H, *et al.* PROSPECT guideline for total hip arthroplasty: a systematic review and procedure-specific postoperative pain management recommendations. *Anaesthesia* 2021;76:1082–97.
- Maffiuletti NA. Assessment of hip and knee muscle function in orthopaedic practice and research. *J Bone Joint Surg Am* 2010;92:220–9.
- Ueshima H, Otake H. Clinical experiences of pericapsular nerve group (PENG) block for hip surgery. *J Clin Anesth* 2018;51:60–1.
- Mysore K, Sancheti SA, Howells SR, *et al.* Postoperative analgesia with pericapsular nerve group (PENG) block for primary total hip arthroplasty: a retrospective study. *Can J Anaesth* 2020;67:1673–4.
- Sandri M, Blasi A, De Blasi RA. PENG block and LIA as a possible anesthesia technique for total hip arthroplasty. *J Anesth* 2020;34:472–5.
- Kukreja P, Avila A, Northern T, *et al.* A retrospective case series of Pericapsular nerve group (PENG) block for primary versus revision total hip arthroplasty analgesia. *Cureus* 2020;12:e8200.
- Johnson RL, Kopp SL, Hebl JR, *et al.* Falls and major orthopaedic surgery with peripheral nerve blockade: a systematic review and meta-analysis. *Br J Anaesth* 2013;110:518–28.
- Stathellis A, Fitz W, Schnurr C, *et al.* Periarticular injections with continuous perfusion of local anaesthetics provide better pain relief and better function compared to femoral and sciatic blocks after TKA: a randomized clinical trial. *Knee Surg Sports Traumatol Arthrosc* 2017;25:2702–7.
- Kronzer VL, Wildes TM, Stark SL, *et al.* Review of perioperative falls. *Br J Anaesth* 2016;117:720–32.
- Singh S. Total hip arthroplasty under continuous pericapsular nerve group block (cPENG) in a high risk patient. *J Clin Anesth* 2021;68:110096.

## Correction: *Preoperative pericapsular nerve group (PENG) block for total hip arthroplasty: a randomized, placebo-controlled trial*

---

Zheng J, Pan D, Zheng B, *et al.* Preoperative pericapsular nerve group (PENG) block for total hip arthroplasty: a randomized, placebo-controlled trial. *Reg Anesth Pain Med* 2022;47:155–160. doi: 10.1136/rapm-2021-103228

The correct affiliation for the corresponding author, Xiangcai Ruan, is:  
Department of Anesthesiology and Pain Medicine, The Sixth Affiliated Hospital, Sun Yat-sen University, Guangzhou, China.

© American Society of Regional Anesthesia & Pain Medicine 2022. No commercial re-use. See rights and permissions. Published by BMJ.

*Reg Anesth Pain Med* 2022;47:e4. doi:10.1136/rapm-2021-103228corr1

