

Femoral triangle block plus iPACK block versus local infiltration analgesia for anterior cruciate ligament reconstruction: an infographic

Eric S Schwenk ¹ 
Rajnish K Gupta ² 

ABSTRACT

Anterior cruciate ligament reconstruction can be painful, and both the femoral triangle block and local infiltration analgesia have been shown to provide effective analgesia after this surgery. A relatively new block, the iPACK (infiltration between the popliteal artery and the capsule of the knee), has been reported to provide posterior knee analgesia. In this triple-blinded, randomized controlled trial of 60 patients, the combination of femoral triangle block and iPACK block reduced opioid consumption for 24 hours postoperatively compared with local infiltration analgesia.¹ However, other pain and functional outcomes were the same in both groups.

¹Anesthesiology, Sidney Kimmel Medical College at Thomas Jefferson University, Philadelphia, Pennsylvania, USA

²Anesthesiology, Vanderbilt University Medical Center, Nashville, Tennessee, USA

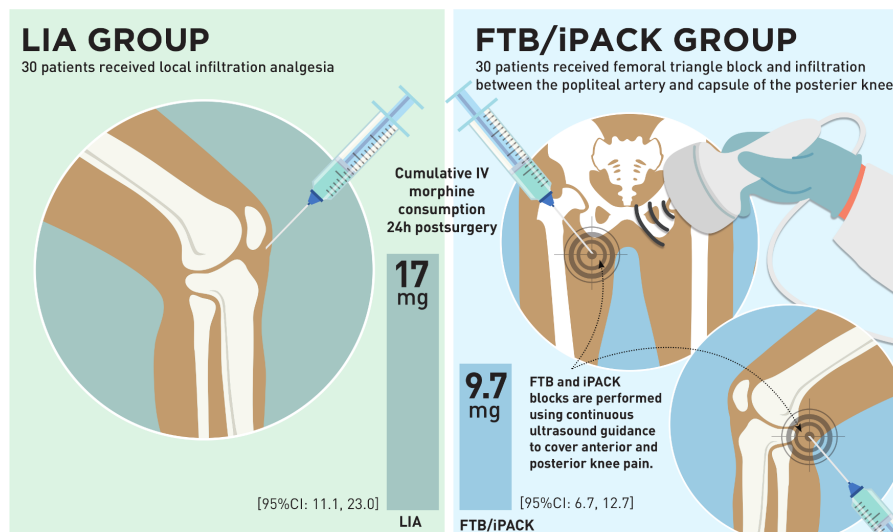
Correspondence to Dr Eric S Schwenk, Anesthesiology, Sidney Kimmel Medical College at Thomas Jefferson University, Philadelphia, PA 19107, USA; prepdrum@gmail.com

Twitter Eric S Schwenk @ESchwenkMD and Rajnish K Gupta @dr_rajgupta

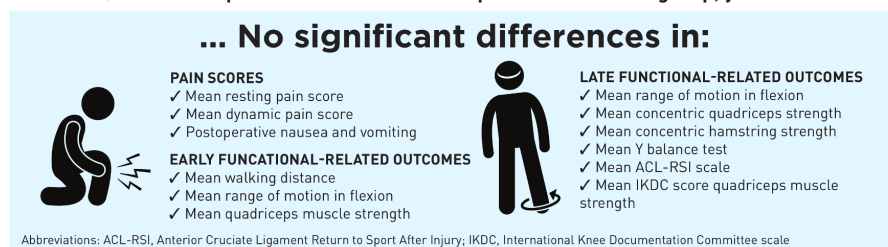
Acknowledgements We would like to acknowledge Jim Snively, artist, of Pittsburgh, Pennsylvania, for creation of this infographic.

Femoral Triangle Block + iPACK Reduces IV Morphine Consumption

during the first 24 hours after ACL reconstruction compared with local infiltration analgesia, without effect on other pain-related and early/late functional-related outcomes.



FTB/iPACK Group received 42.9% less morphine than the LIA group, yet still had...



Martin R, Kirkham K, Ngo T, Gowers E, Lambert J, Albrecht E. The combination of femoral triangle block and infiltration between the popliteal artery and the capsule of the posterior knee (iPACK) versus local infiltration analgesia for analgesia after anterior cruciate ligament reconstruction: a randomized, controlled, triple-blinded trial. *Reg Anesth Pain Med*. 2021;46(x-x). Infographic by Jim Snively

Regional & Pain Anesthesia & Medicine

Collaborators Jim Snively.

Contributors Both authors edited the infographic and approved the final manuscript.

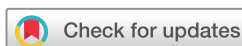Funding The authors have not declared a specific grant for this research from any funding agency in the public, commercial, or not-for-profit sectors.

Competing interests None declared.

Patient consent for publication Not required.

Provenance and peer review Commissioned; internally peer reviewed.

© American Society of Regional Anesthesia & Pain Medicine 2022. No commercial re-use. See rights and permissions. Published by BMJ.



To cite Schwenk ES, Gupta RK. *Reg Anesth Pain Med* 2022;47:64.

Received 8 June 2021

Accepted 9 June 2021

Published Online First 18 June 2021



► <http://dx.doi.org/10.1136/rapm-2021-102631>

Reg Anesth Pain Med 2022;47:64.
doi:10.1136/rapm-2021-102942

ORCID iDs

Eric S Schwenk <http://orcid.org/0000-0003-3464-4149>
Rajnish K Gupta <http://orcid.org/0000-0003-3401-4737>

REFERENCE

- 1 Martin R, Kirkham KR, Ngo THN, et al. Combination of femoral triangle block and infiltration between the popliteal artery and the capsule of the posterior knee (iPACK) versus local infiltration analgesia for analgesia after anterior cruciate ligament reconstruction: a randomized controlled triple-blinded trial. *Reg Anesth Pain Med* 2021;46:763–8.